1-1-1966

A histomorphological study of age changes in the canine adrenal gland.

Ronald Loral Hullinger
Iowa State University

Recommended Citation

Hullinger, Ronald Loral, "A histomorphological study of age changes in the canine adrenal gland." (1966). *Retrospective Theses and Dissertations*. 18317.
https://lib.dr.iastate.edu/rtd/18317

A HISTOMORPHOLOGICAL STUDY OF AGE CHANGES IN THE CANINE ADRENAL GLAND

7w

by

Ronald Loral Hullinger

A Thesis Submitted to the
Graduate Faculty in Partial Fulfillment of
The Requirements for the Degree of
MASTER OF SCIENCE

Major Subject: Veterinary Anatomy

Iowa State University
Of Science and Technology
Ames, Iowa

1966

TABLE OF CONTENTS

INTRODUCTION

The principle destiny of living organisms is an encounter, in this mass, space and time existence, with a moment in time at which the individual terminates. The individual undergoes numerous dynamic processes from the moment of fertilization until the moment of death. Within this framework of time the individual may be said to progressively "age". With the passage of time the dynamics of life's processes bring about constant change in nearly all organ systems, organs, tissues and cells. These changes accompanying an increase in age then manifest themselves in morphological and functional alterations in the life of the individual and direct the biological course and absolute extent of that life. These alterations are called "age" changes.

In a more specific sense age changes indicate those alterations occurring in an organism after a period of maximal activity has been achieved. In this context age changes then become those changes manifested during the period of decline in a biological life or, as it is generally referred to, the period of aging. This is the area of the gerontologist's primary concern.

Age changes are of a general versus a unique nature, in that they are manifested by nearly all individuals sharing a given environment.

To gain a basic understanding of the causes and effects of aging is the aim of many gerontological studies today. Such a knowledge does and will continue to provide for advances in both animal population and human geriatrics. The socio-economic importance of adding reproductive and productive years to the lives of the livestock population is at once obvious in today's world. Man's companion animals also benefit from these findings. Most importantly these findings aid in perfecting a capacity to prevent, retard, repair and treat the effects of time manifested in the human population.

The ultimate objective of aging research is surely to delineate effectively and to gain an understanding of the basic changes of structure and function which occur in an individual and eventually end in termination of that individual. To properly evaluate those changes occurring with age in our wild animal population and human populace, one must observe many species to note basic similarities and dissimilarities in the pattern of age changes in organ systems, organs, tissues and cells.

The role of the endocrine organs in aging processes has long been a topic of interest to gerontologists. No small amount of attention has been directed toward accessing the role of the adrenal gland in aging. Major attention has been aimed at evaluating the specific role of the adrenal cortex in these processes.

There is a considerable variability among the mammalian species with regard to adrenal gland histomorphology and much can be gained from comparative gerontological research. Descriptive data concerning all species as they age would be of unquestional value when considering biological aging <u>in toto</u>.

To delineate the "normal" aging process versus the "pathology of old age" is of equal importance and difficulty. The need for carefully designed and controlled experimentation whereby more definitive conclusions can be drawn concerning what is "normal" physiological aging and what is pathological aging is clearly evident.

The objectives of the research reported herein concerning the histomorphological changes accompanying age in the canine adrenal have accordingly been two: (1) to contribute to the understanding of the normal morphological changes of aging in the canine adrenal and (2) to implement observations and evaluations of the so-called primary or secondary age changes in the canine adrenal and the possible role of these changes in the aging process.

LITERATURE REVIEW

Definitions of Criteria and Terms

The study of aging is known as gerontology (Andrew, 1952). Gerontology is a study of the biology of aging and the control of age processes (Comfort, 1964). Aging, when defined as a decline in vigor accompanying the passing of time, accordingly takes on a different connotation, that of senescence. Cowdry (1942), emphasizing the magnitude of the task of gerontological research, stated ". . . since all living organisms pass through a sequence of changes, characterized by growth, development, maturation and finally senescence, the question of aging presents a broad biological problem."

To properly evaluate changes due to aging one must establish criteria upon which the evaluation can be made. Strehler (1962) offered the following criteria which can be used to distinguish biological age changes. (1) Universality. Those changes observed and attributed to the aging process must be seen in all older members of that species. (2) Intrinsicality. The causes of these changes must be intrinsic and not merely environmental variables. (3) Progressiveness. The changes at the tissue and molecular level are gradual processes and are thus manifested gradually at the tissue and organ level. (4) Deleteriousness. One must evaluate these changes to determine if they are in effect deleterious versus developmental or growth changes. One must be concerned with the effect of a given change—an impaired or improved functionability.

There are comprehensive reviews of aging covering extensively the theories of aging mechanisms, research findings, and problems encountered in the field of gerontology (Comfort, 1964; Strehler, 1962; Bourne, 1961; Cowdry, 1942; Lansing, 1952).

The Adrenals

Historical

Eustachius (1563) is believed by some to have been the first to describe the adrenals in man (Bourne, 1949; Hartman and Brownell, 1949). Goldzieher (1944) commented on a copperplate set found in the Papal library one of which was dated 1552 by Eustachius who later, in the year 1563, described the organs. However, Goldzieher (1944) credited Galen as the first to describe the adrenals. This is disputed by Bourne (1949) who found no evidence in any of the works of Galen of his having described the adrenals.

Bourne (1949) presented an interesting account of how Della-Chiaje (1837) came to conclude that Moses knew of the adrenal glands and how Blanchard in 1882 denied this to be the case.

Eustachius described the adrenals as Glandulae renibus incumbentes and believed they were perhaps accessory kidneys. Bourne (1949) credits Winslow (1732) with the "first accurate description" of the adrenal anatomy and credits Ecker (1846) with the first published detailed account of the microscopic structure of the adrenal.

Development of the adrenal gland

The mammalian adrenals are formed by two different germ cell types; the cortex is derived from mesoderm and the medulla has its origin from neuro-ectoderm. Bourne (1961) stated that some of the primitive neuroectodermal cells become capsule cells. The glomerular layer and beginnings of the fascicular layer are present at birth; however, the zona fasciculata and zona reticularis become well delineated within a few months (Keene and Hewer, 1927).

Of considerable importance as it relates to the human and primate adrenal development is the fetal cortex. Elliott and Armour (1911) were the first to describe the fetal cortex. Between the adult cortex and medulla they noted a distinct zone of cells which they termed the fetal cortex. The gradual degeneration of these cells after birth was compensated for by growth into the area by cells of the adult cortical mass. Hill (1930) found this zone in other primates. A similar zone, the "X" zone, was described in mice and rats by Howard-Miller (1938). She observed that in mice the zone degenerated and formed a band of connective tissue at the cortico-medullary border but in rats she noted the zone became the adult zona reticularis.

A postnatal, structural fetal cortex has not been reported in the canine to the knowledge of this investigator. Bourne (1961), however, observed that "there is considerable evidence that some representative of the juvenile or "X" zone is present in the adrenals of all mammals . . . ."

Blood supply and venous drainage

Flint (1900) spoke of the richness of the blood supply of the canine adrenal and he described a hilus region of the gland which provided a general gross arrangement into anterior and posterior subdivisions. The hilus was noted as the area of greatest blood vascular supply. According to Smithcors (1964) the adrenal, in relation to size, receives, with the exception of the thyroid, more blood supply than any other organ. Smithcors described the major blood supply as arising from three primary sources; (1) a cranial adrenal artery arising from the phrenic artery, (2) a middle adrenal artery as a branch directly off of the aorta, and (3) a caudal adrenal artery from the renal artery. He also mentions arterial supply from branches of the accessory phrenic artery, lumbar arteries and the cranial mesenteric or celiac artery. Flint (1900), again emphasizing the division of each gland into an anterior and posterior lobe, described the major supply as follows:

1. A. phrenica supplying 1-2 branches to anterior lobe
2. A. phrenica accessoria supplying 2-3 branches to anterior lobe
3. A. abdominalis supplying 2-4 branches to posterior lobe
4. A. lumbalis supplying 2-6 branches to posterior lobe
5. A. renalis supplying 4-6 branches to posterior lobe

The capsule has been described as being richly supplied with a network or plexus of arterioles. Larger vessels formed from these or apart from the plexus passed into the gland substance (Smithcors, 1964). A more or less distinct blood supply was described for each of the three major gland components—the capsule, cortex and medulla. The relationship between cortical parenchymal cells and the capillary networks was such that all of the parenchymal cells could have contact with a nutrient vessel or a pathway of excretion. This relationship might be seen only on one side of the cell or, quite possible, the cell would be surrounded by capillary elements. As the capillaries emerged from the cortex, sinuses were formed in the innermost regions of the cortex and in the medulla (Smithcors, 1964). However, some larger arterioles were observed to pass directly to the medulla without ramifying in the cortical elements (Flint, 1900).

The capsule was noted to possess a separate venous drainage by way of a capsular venous plexus observed just beneath the arterial plexus of the same area. These plexuses were drained by venous channels passing to the phrenic, lumbar and renal veins. The lumbar vein was described as passing the region of the hilus of the gland where it anastomosed with the venous drainage of the medulla to form the adrenal vein (Flint, 1900). The blood sinuses of the inner cortex and medulla drained into medullary veins. These medullary veins formed the right and left adrenal veins and then passed, after anastomosing with the lumbar veins, to the postcava and renal vein, respectively (Smithcors, 1964; Flint, 1900).

Innervation

As in the case of the blood supply, the innervation of the adrenal is likewise extensive (Bourne, 1961). The main innervation is via the splanchnic nerves. The remaining supply, Smithcors (1964) described as being from the "celiac ganglion and the first three or four ganglia of the abdominal sympathetic chain." From a capsular plexus of myelinated and nonmyelinated fibers branches were observed to pass into the parenchymal areas. Smithcors also described fibers which enter the cortex and "form small plexuses around the cell groups and blood vessels of its three zones." Bourne (1961) questioned the innervation of cortical elements and pointed to a lack of evidence for such in the human and cat. He supported those who had described all nerves as passing to the medulla where they innervated cell groups. He believed that Alpert (1931) may have described reticular fibers in cortical elements, instead of nerve fibers. Many myelinated fibers were described by Bourne as passing directly to the medulla through the cortex, and many sympathetic ganglion cells have been observed in the medulla.

Capsule

Vincent (1922) presented a number of illustrations of the canine adrenal and prominent in these were the thick capsular elements. Bachmann (1954) described the adrenal capsule of all species, in general, as being composed, in large part, of collagenous and elastic fibrous elements. From the inner surface of the capsule, trabeculae were seen to penetrate the cortex and give rise to fibrous networks which served to support the parenchymal cellular elements. Bourne (1949) is among those who have reported elastic elements and smooth muscle in the capsule of the adrenal.

Bachmann (1954) felt that the elastic elements and muscle fibers in the adrenal were not in keeping with the view of a "static organ" concept. He viewed the capsule in relation to the dynamics of the gland, as in locomotion or contracting of the gland, versus a skeleton of support.

According to Bachmann (1954), cortical parenchymal loops may be extruded into the capsule in some foci. The connections between these and the cortical parenchyma were narrow and even found to be lacking, thus forming intracapsular complexes. He saw this to be a process of isolation after being extruded into the capsule and referred to this as an occasional "prolapse" of the cortex into and through the capsule.

Zwemer, Wotton and Norkus (1938) observed that new glandular cells were obtained from pluripotential cells of the inner cortical layer to replace those degenerating in the inner cortical area in the monkey, cat and man. Others have also supported this finding (Gruenwald, 1942 and

1946; Gruenwald and Konikov, 1944). This procedure for cortical cell replacement has been reported in the dog by Gruenwald and Konikov (1944). They observed small cortical nodules from which they found no communications with the cortex. They proposed, however, that, when the animal is stressed excessively, large masses of these cells might extend out of the capsule and fuse with the glomerular elements.

Elias (1948), in his work with the adrenals of the horse, pig, ox, goat and sheep, confirmed the process of genesis of cortical cell elements from the capsule. He stated, "Cells of the capsule enlarge along a broad front, move downward and are gradually transformed into cortical cells and incorporated into the cortex." He also described the genesis of fewer numbers of cells individually from the capsule to become part of the glomerulosa. He went on to report "parenchymatous nodules of cortical tissue were formed in the capsule by local accumulation of cells. These are pushed downward by an unknown force."

de Groot and Fortier (1959) showed that, in rats, regeneration from enucleated capsule elements, left with their blood supply undisturbed, began within one week, and that the gland had been restored nearly to its original cortical mass after 6-8 weeks with normal zonation, except for a slightly enlarged zona glomerulosa.

Anderson (1961) reported on human materials and referred to "common nodular hyperplasia" of the adrenal cortex which is "characterized by multiple, bilateral, small nodules of hyperplastic adrenal cortical tissue in the cortex, the capsule or the periadrenal fat." He referred to their alleged increase in frequency with age and to the fact that their incidence due to sex differences had not been established. He noted that they may or may not be encapsulated and that both forms may be in the same gland.

Karsner (1950) has shown that in many cases even the periadrenal nodules are connected by a bridge of cortical tissue to the cortical elements.

Bachmann (1954) discussed, at considerable length, the role of the capsule in providing communication with the environment; the capsule communicates with the peritoneum and with the periadrenal fatty connective tissue. As reported by Bachmann (1954), Velican (1949) emphasized this communication at length. He attempted to show evidence of a functional relationship between the periadrenal fatty connective tissue and the cortex and pointed out that it was part of the brown fat connective tissue and, as such, represented glandular tissue belonging to the reticulo-endothelial system.

Cortex

The cortex of the canine adrenal is divisible into three relatively distinct zones: the zona glomerulosa, zona fasciculata and zona reticularis.

The outer zone bordering on the capsule is the zona glomerulosa which occupies about 25% of the total cortex (Baker, 1937). The zona fasciculata is the largest of the three cortical zones and it is located centrally in the cortex, occupying about 60% of the cortical parenchyma. The zona reticularis occupies the remaining 15% of the cortex and occurs at the medullary border (Smithcors, 1964).

Working with the feline adrenal cortex, Bennett (1940) described centripetally migrating cells of the cortex which he described as progressively moving from the outer to the inner regions of the cortex. He described the areas as four in number: presecretory, secretory, postsecretory and senescent. Others have observed the derivation of cortical elements from undifferentiated cells of the inner capsule. These cells are described as first appearing in the zona glomerulosa and then becoming modified as they pass from one functional area to the next as they move centrally toward the medulla (Wotton and Zwemer, 1943).

Mitchell (1948), working with rats, presented evidence to indicate that the capsule contributed few new cells to the cortex after the first 2-3 weeks of postnatal life. He observed two areas of high mitotic activity, the zona glomerulosa and the outer one-third of the zona fasciculata.

Zwemer, Wotton and Norkus (1938) observed that adrenal cortical cell elements originally arise from the capsule and then change in type as they migrate through the zona glomerulosa, zona fasciculata and zona reticularis, respectively. Graham (1916), Hoerr (1931), Baillif and Baker (1938), Gruenwald and Konikov (1944) and Elias (1948) all support this general process of cortical cell morphogenesis.

Gross (1964) termed this process whereby the parenchyma is steadily replaced, "morphogenetic regeneration." Brenner (1963) labelled newly divided cells of the mouse cortex with tritiated thymidine and showed that most activity occurs in the inner glomerulosa and outer fasciculata. The labelled cells eventually disappeared, indicating possible degeneration and removal in the zona reticularis.

The three primary zones of the dog's adrenal are not always distinctly delineated (Smithcors, 1964). The zona glomerulosa is composed of "flask-shapped masses of tall columnar cells which were arranged side by side in a single layer, Hill (1930)." Smithcors (1964) spoke of ". . . coiled cell columns which have a sigmoid or U-shaped arrangement next to the capsule" in this zone. Gruenwald and Konikov (1944) referred to "large epithelial arches with their convexities toward the capsule."

The zona fasciculata is composed of larger ovoid cells (Hill, 1930) arranged in "anastomosing columns . . . at right angles to the capsule" (Smithcors, 1964). These cords are separated by capillaries and vascular sinuses (Flint, 1900).

The zona reticularis is composed of cells arranged in small groupings surrounded by capillaries. The zona reticularis cells are similar in type to those of the zona fasciculata. There is not a regular boundary between the zona reticularis and the medulla but the boundary is distinct (Smith, Calhoun and Reineke, 1953; Hill, 1930).

Hill (1930) suggested that cortical tissue corresponding to the fetal cortex might persist as the deep layer of the adult cortex, the reticularis.

Medulla

Vincent (1922) described the medulla as being formed of ". . . columns or bundles of cells with very little connective tissue associated with them and containing a number of medium sized spaces." Smithcors (1964) listed the percentage of the entire adrenal occupied by medullary tissue as 10-20 percent. Flint (1900) pointed out that often one may observe medullary cell groups within the cortical area. He described these as islets of migrating tissue which were trapped as the cortex matured.

Significance of the Adrenal Gland in the Aging Process

A primary role of the adrenals as a cause of the aging process has not been widely accepted (Korenchevsky, 1961; Jayne, 1953).

Rogoff and Stewart (1926, 1928) reported in dogs that one-twentieth of one gland, if it has an adequate blood circulation, can maintain a healthy life. Carlson (1942) also spoke of the very large "safety factors" involved and suggested that perhaps the main aging related role of the adrenals might be in regulating metabolic processes. Comfort (1964) observed, concerning the role of the endocrines in the aging process, that the ". . . supposedly primary and 'senile' histological appearances in glands require serious investigation before they are made the basis for statements that senescence is a consequence of the deterioration of a particular gland."

Rothenbacher and Shigley (1966), studying canine, geriatric, clinical patients, suggested that stress induced hyperplasia can be followed by chronic cortical insufficiency and degenerative changes leading to adrenocortical apoplexy. They suggested that adrenocortical apoplexy should be considered as an independent, primary cause of death in the geriatric patient.

Histomorphological Age Changes in Adrenal Glands

Cooper (1925) was among the first to study age changes in the adrenal glands with age. She described changes in the human from birth to old age. She referred to the initial postnatal involution of the fetal cortex and noted that this cortical zone then gradually became reduced to a thin band of connective tissue at the cortico-medullary border by the end of the first year. By a progressive increase in size, due primarily to zona fasciculata enlargement, maximum gland size was reached at puberty. She described a progressive thickening of the capsule from a narrow band in the young to a wide band in old age. The zona glomerulosa's cellular constituents were observed to change little with age; however, the connective tissue between these arches was seen to increase in amount with age. With advancing age she reported a shortening of the fascicular columns and an increase in the sinus spacing between them. She also described an increase in prominance as a zone to the zona reticularis with age.

Pigment containing cells were observed by Cooper (1925) and Findlay (1920) in the zona reticularis of the human. They were described as appearing first at puberty and then increasing steadily with age.

The main change with age in the human adrenal medulla was described by Cooper (1925) as a thickening of the connective tissue fibers surrounding the medullar cells. She observed no pigment containing cells in this region.

In the aging hampster, Meyers and Charipper (1956) reported the primary changes to be a general increase in the size of connective tissue in the capsule and reticularis. These findings have likewise been observed in the guinea pig by Blumenthal (1945) and in the rat by Dribben and Wolfe (1947).

Yeakel (1946), working with rats, observed cortical nodular hyperplasia and very marked vascular dilatation along with varying levels of medullary hyperplasia with increased age.

Goodpasture (1918) described aging changes in the canine and noted an irregular but smooth macroscopic surface of the adrenals caused by protuberances of 1-2 cm. in diameter from the capsular surface in both glands. Microscopically he observed them to be composed of cortical tissue and as being nonencapsulated. The organs showed cortical irregularities due to atrophy and hyperplasia of elements. He described replacement of parenchymal elements in parts of the reticular zone by fibrous tissue and blood vessels. Also observed was the infrequent occurrence in the reticular zone of cells which he described as in a "seemingly depressed condition" and he went on to describe degenerating cells here. He noted pigment-filled phagocytes as further evidence of degenerative processes in the zona reticularis. Goodpasture observed hyperplastic changes of all three cortical zones; however, hyperplastic areas in the capsule and zona glomerulosa were more commonly seen and he described the cells of these to be like those of the zona glomerulosa, except in the irregularity of cell arrangement. These foci were observed to penetrate the capsule and form "small excrescences" on the surface of the capsule.

Hill (1930) evaluated the primary changes with age in the canine adrenal to be: (1) the development of a prominent connective tissue boundary at the cortico-medullary border, and (2) a more well developed zona glomerulosa.

MATERIALS AND SURVEY OF METHODS

General

Material for the research reported herein was obtained from the Beagle dog colony of the Department of Veterinary Anatomy, Iowa State University. Purebred Beagle dogs were used in all cases.

One of the major attempts in biological aging research, as in all research areas, is to refine the methods and improve the controls. Carlson (1942) stressed the need for controlled sources of materials. He stressed the importance of controlled information regarding nutrition, general health status, heredity, circulatory system health and the status of the entire endocrine system. Cammermeyer (1963) also stresses the importance of an accurate knowledge of some of these variables.

Design of Program

In an attempt to standardize or eliminate any wide variation which might occur due to a few of the more easily standardized variables, the following comprehensive gerontological program was instigated by Dr. R. Getty in the department of Veterinary Anatomy, Iowa State University, Ames, Iowa.

In 1952 a mongrel dog colony was established with the object of providing canine specimens for gerontological research being conducted at that time. The colony grew in size and the procedure of management became standardized. In 1955 a purebred Beagle colony was begun to replace the mongrel colony. Since 1958 the colony has been a purebred Beagle colony. The colony population has been maintained at forty to fifty animals.

The post-weaning diet for all the animals is composed solely of dry commercial dog feed.[1] This diet is self-fed, free choice by means of enclosed, hopper-type self-feeders. Feed analysis showed the diet to be composed of 25% protein, 40% carbohydrates, 7% fat, essential amino acids, vitamins and minerals with one pound of feed providing 1500-1600 calories.[2]

A clean fresh water supply is provided for by an automated watering system.

Concerning the general health status the following procedures are employed. General physical evaluations are made at predetermined regular intervals of three months. Routine fecal examinations serve to determine the gastro-intestinal parasitic involvement. This is maintained at a low level by periodically administering a commercial anthelmintic. As part of the daily routine, the animal kennels are hosed clean with steaming-hot water.

Routine infectious disease prophalaxis involves all of the colony in a rigid program of vaccination for canine distemper and infectious canine hepatitis. As a further preventative measure, an eight foot, solid wooden fence bounds the periphery of the colony and at all points it is located at a minimum of five feet from the colony fences, thus preventing direct contact of colony dogs with stray animals.

Necropsy evaluation at the time of death and specimen collection revealed all animals in good health.

---

[1] Provided by Gaines Dog Food Division, General Foods Co., Kankakee, Illinois

[2] Feed analysis provided by Gaines Dog Research Laboratories, Kankakee, Illinois

In large part the colony is "closed" with reference to influx of new individuals. The breeding program is so designed as to require only a minimal selected number of new parent stock to be introduced. To this end an attempt is made to maintain a certain degree of homogeneity regarding parent stock and offspring with a minimal influx of new strains.

Work concerning the integrity of the circulatory system and morphological picture of the other endocrine organs of these individuals has been reported (Getty, 1962, 1963, 1965; Haensly and Getty, 1965) or is currently being conducted in the Department of Veterinary Anatomy.

Specimens

Adrenals from 56 dogs ranging in age from birth to 13.6 years were used in this study. Dogs of both sexes were used and the accompanying Table 1 provides a description of these animals.

Collection Procedure

Each animal was killed by electrocution. Exsanguination was accomplished by severing the axillary artery and vein. The animals were dissected immediately after death and the adrenals were in the fixative 3 to 5 minutes after death.

Histological Methods Employed

The fixing solutions used in this study were mercury formal-sealine and standard calcium-cadmium procedures.

An attempt was made to remove identical cross sectional segments of mercury formal fixed tissue from a point nearly midway along the length, at such a point that nearly 0.5 cm. of tissue would be taken which would include a portion of the greatest diameter of the gland. This was then embedded in Paraplast, serially sectioned at 6-8 microns and mounted for staining. In some cases full gland longitudinal sections were made according to the same procedure as outlined above.

The same procedure was used to select the macroscopic area for those adrenals fixed in calcium-cadmium which were used for frozen sections. Sections were made at 15 microns with Scientific Products' Histo-Freeze equipped with a sliding surface microtome. The sections were mounted on glass slides with the aid of egg albumin and allowed to air dry prior to staining.

Staining procedures used included:

1. Routine Hematoxylin and Eosin (AFIP, 1960)
2. Mallory's Triple (as modified by Crossman, 1937)
3. Heidenhain - Van Giesen - Weigert (as adapted by Getty, 1949)
4. Oil Red O (as modified by Bell, 1959)
5. Schultz Cholesterol (as modified by Weber, Phillips and Bell, 1956)

Photographic macro reproductions were made with a Leitz Aristophot II with Macro-Dia equipment and a 4 x 5 inch billows camera. The film used was Polaroid 4 x 5 Land Film Packets, type 55 P/N.

Photographic micro reproductions were made with a Leitz Ortholux research microscope equipped with 6V 30W lamp attachment, a FAS photo-tube, plano objectives and Orthomat microscope camera. The color reproductions were produced on Kodachrome II professional film and were commercially processed.

Quantitative Methods

Biometric observations were made to complement the qualitative evaluations of the age changes mentioned in this work. In large part the observations reported herein are not subject to the laws of mathematical probability. However, some measurements were rather easily made and it seemed that an evaluation of their relative value might be of interest.

An effort was made to obtain the measurement data in the most objective manner possible. The identity of each animal was coded so that their ages were not revealed to the observer until all data had been gathered. An independent observer made the selection of individuals and the order in which they were to be evaluated.

Cortical zonary measurements were made to evaluate possible relative increases or decreases in zone widths with advancing age. Measurements of the capsular and zonary widths were made with a Bausch and Lomb filar screw micrometer eyepiece. These measurements were routinely taken at four randomly chosen directions of the gland by placing the specimen out of focus and selecting the new area before refocusing. Each direction was fixed with respect to the others at 90° separations (Chalkley, 1943). The capsule, glomerulosa, fasciculata and reticularis were all measured on the same radial line. A mid-zonary circumferential measurement was made from 8 x 10 photographic enlargements and, after correcting for magnification, was used to determine, with the width measurement, the total area represented by each zone. The constant factor of 8 μ thickness multiplied by the area gave an estimate of the volume of the respective zones in this, and only this, section. From these volume measurements calculations of percent composition were made, the chief concern being with relative not absolute measurements. Percentages were determined by dividing the total volume of the respective zone by the total volume of the cortex (the sum of volumes of all three zones).

In order to determine the cell counts the total cross sectional enlargements were standardized so that each gland would approach an enlargement size of 8 x 10 inches. This print then served as a vehicle for sampling locations in the zona fasciculata at which cell counts were to be made. The 8 x 10 inch print of each adrenal was placed under a gridded overlay which was numbered at the intersections of the grid lines. By reference to a table of random numbers, the numbers of grid points were obtained. At each of these chosen grid points a triangular apparatus was placed, rotated and allowed to come to rest on the overlay surface. Pin pricks were then made through the overlay and into the underlying photograph whenever the apices of the triangle came to rest on the gland. Closer examination then revealed if the points fell within the zona fasciculata. The first ten points to do so were considered as the selected foci at which counts of cells per unit area were to be made.

By reference then to the original slide under the microscope and by aid of a net micrometer, 5 x 5 mm. divided into 0.5 mm., counts were made at a magnification of 430X at each focus. To minimize measurement error, readings were made at each focus until repeatability was considered sufficient to indicate a reliable count of nuclei per unit area and an index of cell numbers per unit area.

OBSERVATIONS AND RESULTS

To evaluate more definitively comparative changes with age in the adrenals of the animals involved in this work, the following grouping with respect to age was adopted. (Also see Table II.).

Group A — Birth
Group B — 4-57 days; 0.01-0.2 years
    Subgroup B1 — 4 and 9 days
    Subgroup B2 — 14 days
    Subgroup B3 — 28 days
    Subgroup B4 — 36 days
    Subgroup B5 — 57 days
Group C — 97-206 days; 0.3-0.6 years
    Subgroup C1 — 97 and 100 days
    Subgroup C2 — 198-206 days
Group D — 239-367 days; 0.7-1.0 years
Group E — 337-1520 days; 1.2-4.2 years
Group F — 2192-3667 days; 6.0-10.0 years
Group G — 3791-4980 days; 10.4-13.6 years

Group A: Birth (3 Specimens)

The adrenals of this full term age group were differentiated to such a degree that the capsular, cortical and medullary elements were discernible. However, the more definitive demarcation of boundaries and the differentiation of cortical zones were not observed.

Capsule

A highly cellular adrenal capsule was observed to be morphologically distinct from the parenchyma. It was characterized by a dense accumulation of cells at the periphery of the developing gland mass and the occurrence of loose collagenous filaments in the interstices between cells. These collagenous fibers appeared only to have begun to assume the orientation which would eventually result in a paralleling of the circumference of the gland. These collagenous fibers, however, provided a structural framework within which the capsular cells were oriented. From these collagenous elements it was possible to trace fine fibers into all of the parenchymal areas of the cortex and into the medulla where they formed supportive stromal networks for the respective cells.

The cells occurring within the capsule contained a nucleus differing little from the nuclei of those cells observed in the adjacent cortex. Those nuclei were large and ovoid with chromatin granules and the cells were observed to be oriented with the circumferential direction of the gland.

The capsule seemed more cellular in the innermost, as opposed to the outer, part of its structure, but this was not markedly evident. The cells and collagenous fibers of the outer part of the capsule were observed to communicate and to be continuous with the loose areolar connective tissue surrounding the gland. The inner cellular elements appeared, at a limited number of points, to be in direct continuation with the underlying parenchymal cells. This was most clearly evident in areas where the larger capsular trabeculae penetrated into the cortex.

This general capsular morphology was characteristic of the larger portion of the capsule. However, wherever the developing capsule was in apposition with the mesothelial membrane (parietal peritoneum), the development of the capsule was observed to be much advanced. In these areas the appearance of the fibrous and cellular elements was characteristic of the following age group.

Also of interest in relation to the capsule were the periadrenal fatty tissues. These aggregates of cells were observed as isolated nodules of considerable size in the pericapsular area. The cells of these aggregates were characterized by a morphology, both nuclear and cytoplasmic, which was quite similar to the cortical parenchymal cells. Many of these showed vacuolation and a few had developed to the "signet ring" cells of fatty tissue.

Arterioles and capillaries pervaded the capsule, forming a very extensive network of capsular and subcapsular vessels.

Zona glomerulosa

Only a hint of the characteristic, mature, arcade orientation of this zone was observed. The cell cytoplasm appeared to be slightly more eosinophilic than the cellular components of the zona fasciculata and they were of a short columnar morphology. In some areas just beneath the capsule, a continuous column composed of cells arranged side-by-side was observed to have a contortive orientation.

Zona fasciculata

A morphological separation, or boundary, between this zone and the zona glomerulosa was very subtle. The cells of one zone blended almost imperceptively with the other.

The cells of this zone were cuboidal and possessed an ovoid nucleus which had a sparse distribution of chromatin granules therein. Many cells had a vacuolated cytoplasm and the characteristic "spongiocyte" appearance. The cells were not arranged into cords, but were in a rather random arrangement which was generously supplied by an equally random capillary sinus blood supply.

A few groupings of medullary cells were observed interspersed throughout the cortical regions.

Zona reticularis

There was no morphological evidence suggestive of a zona reticularis in the cells adjoining the medulla.

Medulla

The cortico-medullary border was not well defined. There were numerous small aggregates of medullary cells observed within the cortex. The medulla was composed of large, light staining cells with a basophilic nucleus. They were randomly arranged cells supported by delicate connective tissue networks. The medullary veins and some venous sinuses were well formed.

Group B: 4-57 Days (9 Specimens)

Subgroup B1: 4 days and 9 days (2 specimens)

Capsule The capsule remained quite cellular at this age. However, the fibrous elements were increased in amount and organization. This fibrous change was most prominent in the outer one-half of the capsule. Also, collagenous fibers were seen to have passed, at frequent intervals, from the inner surface of the capsule, and at right angles to the capsule, the full depth of the zona glomerulosa. At this point, the border between the zona glomerulosa and zona fasciculata, these small trabeculae were observed to branch and pass laterally until they joined with the neighboring trabecular branches. Morphologically this produced a relative "isolation" of some glomerular cell bundles. Delicate fibers then were observed to continue radially from this area through the cortex and into the medulla.

Zona glomerulosa The glomerulosa was observed to have differentiated considerably compared to group A. The cells were noted to be elongated columnar cells with a cylindrical nucleus located midway in the cell. Numerous vacuoles indicated a goodly amount of lipid storage in the cytoplasm. The cells were in columns and the columns were arranged as arches, the apexes of which were just beneath the capsule and the bases of which were continuous with the zona fasciculata cells. The area was richly supplied with capillary sinuses which pervaded the entire zone. These were seen on the outer margin of the arcades, between the arcades, and also above the arcades, separating them from the capsule. In the inner cleft into the arcade there also was a capillary sinus. Thus, each of the columnar glomerulosa cells had access to a capillary sinus at both of their cellular poles.

Zona fasciculata The cells of this zone were partially arranged in cords of cells radiating from the medulla. In those areas where this arrangement was observed, there were capillary sinuses between the cords. A few medulla-like cells were observed isolated in the cortex.

Zona reticularis These specimens presented no morphological evidence of a zona reticularis.

Medulla Although it appeared that some medullary cells were still in the cortical parenchyma, the cortico-medullary border was defined by a fine fibrous band separating the cortex and medulla. The cells were arranged in groups of cells which were bounded in some areas by large medullary sinuses. The cell cytoplasm was pale and less eosinophilic when compared to the cells of the fasciculata and their nuclei were small and light staining.

Subgroup B2: 14 days (2 specimens)

The adrenals of the two week old beagle dogs were very cellular and showed considerable structural detail.

Capsule A very delicate and relatively very thick cellular capsule contained distinct collagenous elements but these were still not predominant in the capsular structure. Trabeculae, arising from the capsule and rich in cellular elements, were observed to penetrate into the parenchyma of the cortex. Upon termination of these trabeculae their cellular elements seemed to blend very subtly with the adjacent parenchymal structures.

The capsule was divided into two rather distinct morphological zones. The outer area, which composed approximately one third of the total capsular width, contained a higher percentage of collagenous fibers. The nuclei observed here were indicative of a more mature cell type as evidenced by their elongated, ovoid structure which was embedded in the collagenous material. These nuclei stained lightly basophilic with clumps of chromatin material being scattered throughout. This outer capsular zone was found in most areas to be closely applied to the remainder of the capsule, but in regions of periadrenal fat or pericapsular nodules of cortical tissue it was seen to bifurcate and pass in such a manner as to surround these areas, enclosing them within what was, many times, a very delicate capsule. The inner two-thirds of the capsule contained a few collagenous fibers, but mostly it was composed of cells lacking in cytoplasmic outline and detail, but whose nuclei were large and circular to ovoid in morphology. The karyoplasm of these cells stained lightly with routine H & E staining and rather large chromatin granules were dispersed throughout. These nuclei were very numerous in this inner zone indicating that a large number of cells were embedded within the collagenous framework. In those areas where the capsule passed over an arch of underlying glomerular tissue, or the interval between trabeculae, the nuclei were seen to become elongated and the collagenous elements were increased. There was no continuation of capsular and cortical elements at these areas.

Triple staining also revealed that delicate connective tissue strands passed deeply into the cortex and gave rise to secondary supporting fibers for the parenchyma.

Within the capsule there was a limited number of foci of intracapsular cortical tissue. This tissue occurred as nodular isolates which, on serial section, were, in most cases, observed to be connected with the zona glomerulosa by bridges of cortical tissue passing through the capsule. One nodule was observed to be covered with a delicate connective tissue capsule and located in the periadrenal fat apart from the main body of the gland and connections between this nodule and the cortex could not be established.

The periadrenal fat also contained, besides the normal signet ring cells, diffuse arrangements of cells which, morphologically and by the routine staining methods, closely resembled the cortical parenchyma. These cells were seen interspersed randomly between the mature fat cells which were seen only as signet rings. Many of them were vacuolated as were the spongyocytes in the zona fasciculata.

Zona glomerulosa A few arches of parenchymal cells were observed in this zone, but for the most part the cells were arranged in compact bundles beneath the capsule and between the trabeculae. Their morphology closely resembled low columnar cells and their cytoplasm was eosinophilic and granular with a few vacuoles. The nuclei were spherical and only slightly smaller than the nuclei of those cells of the inner capsular zone. These cells appeared to be continuous with the fascicular parenchyma.

Zona fasciculata The fascicular zone cells were not all arranged in the radiating cords. Triple staining revealed also that aggregates of these cells were randomly dispersed in a network of fine connective tissue fibers and showed no pattern of orderly arrangement. The cells were cuboidal with a large amount of vacuolated cytoplasm. The cytoplasmic network which remained was very eosinophilic. The nuclei were large, vesicular and rounded containing scattered chromatin granules and were only faintly basophilic. Within this zone several foci of medullary cells were seen.

Zona reticularis There was no zona reticularis as evidenced by staining or morphological properties of cells adjoining the medulla. These cells resembled, in these respects, the cells of the zona fasciculata.

Medulla There were no significant observed differences from the previous descriptions above.

Group B3: 28 days (2 specimens)

Capsule In these specimens the capsule showed an increase in the collagenous fiber content. The large vesicular nuclei, so prominent in group A, subgroup B1 and B2 now indicated a more differentiated cell type, being smaller, oval to elongated and more basophilic. However, those cells near the inner margin of the capsule retained those nuclear properties ascribed to the cells occupying a similar position in those groups previously described.

The trabeculae arising from the capsule were smaller but more numerous than discussed above. The larger trabeculae gave rise to connective tissue fibers which penetrated the parenchyma to the cortical-medullary border where they were observed to bifurcate and run parallel along this border as delicate collagenous fibers. Intracapsular nodules of parenchymal cells were observed in a limited number of areas. The periadrenal fat showed evidence of the diffusely arranged cells, described above, which appeared to be very similar to the cortical cell types.

Zona glomerulosa The parenchymal cells of this zone were elongated and columnar and their cytoplasm was highly vacuolated and faintly eosinophilic.

The centrally positioned nuclei were elongated to conform to the cellular morphology. The cells were arranged parallel to each other and disposed in arches which were positioned between the delicate trabeculae emerging from the inner margin of the capsule. At the inner margin of the zona glomerulosa the cell type changed in a very narrow zone to a more elongated, narrow (laterally compressed) columnar cell. This zone was compact and uniform in width. These cells seemed to be associated with, or supported by, those small trabeculae ending at the junction of the zona glomerulosa and zona fasciculata. This was interpreted to be the intermediary zone described by Nicander (1952).

Zona fasciculata The cells of the zona fasciculata were, in some areas, arranged in long cords of cuboidal cells which seemed to radiate from the medulla out to the intermediary zone. The nuclei were rounded and took a basophilic stain with H & E. The cytoplasm was highly vacuolated and the remaining cytoplasmic meshwork was eosinophilic. Running between the cords were capillary sinuses which seemed to have their origin in the vortex of the concavity formed by the glomerular arches and then continued, between the fascicular cell cords, to the medullary region. As these sinuses approached the medulla they appeared to increase in number and their arrangement became more random.

Zona reticularis A zona reticularis per se was still indistinct. However, as the cords of fascicular cells approached the medulla, they were observed to deviate laterally and run parallel to the cortical-medullary border. In some areas they were arranged in rows and in other areas, due to the sectioning angle, they were crowded into cell aggregates. As mentioned above, the sinusoidal spaces were frequent and they occupied a considerable percentage of the region. In this age group no histochemical differences were observed between these cells and those of the fasciculata but, based on the morphological appearance of these cells, a reticularis-like zone was evident.

Subgroup B4: 36 days (2 specimens)

Capsule The capsule of these 36 day adrenals differed little morphologically from the description given the capsule of previous specimens. Intracapsular and pericapsular nodules of cortical tissue were seen and the periadrenal fat showed the diffuse parenchymal-like elements interspersed between fat cells. In one such area an islet of cortical tissue was observed in the periadrenal fat. The vascularity in these areas was very extensive.

Zona glomerulosa The cellular morphology in this region was little different from that described in previous subgroup B3. However, in some areas the arrangement of the cells revealed that the arches formed by the columns of cells were continuous, it appeared, at their inner ends, with the adjoining arcade by a communication "under" the trabeculae. The intermediary zone was indistinct.

Other parenchymal elements   These elements presented few differences from those described in subgroups B3 for their respective zones.

Subgroup B5: 57 days (1 specimen)

Capsule   The capsule observed in this age group showed a progressive increase in collagenous elements with a decrease in cellularity when compared to the previous age group. The morphology and occurrence of the capsular cell was much like that noted above in group B, with the exception that the large cell-rich trabeculae were decreased in number. The parenchymal-like cells contained within the periadrenal fat were more difficult to observe and it was noted that the space they had normally occupied, between the signet rings in the tissues previously observed, had decreased in size.

Zona glomerulosa   This zone appeared to be elongated with more acute arches of cells. The eosinophilia and basophilia of the cytoplasm and nucleus, respectively, were more pronounced. The pale, highly vacuolated cytoplasm contained an elongated cylindrical nucleus. These cells, in some areas, appeared to be continuous with the zona fasciculata parenchyma. Still, in other areas, there was an indication of the morphological changes characteristic of the intermediary zone before the appearance of the cuboidal, highly vacuolated spongyocytes of the zona fasciculata.

Zona fasciculata This zone still did not appear to be fully organized into the radiating cords which were replacing the random aggregations of parenchymal cells.

Zona reticularis As the fascicular cords were followed toward the medulla, they were observed to deviate laterally. Concurrently, the cytoplasm of some of these cells in this region became more dense, highly granular, and eosinophilic. Their nuclei were more homogeneous, shrunken, and basophilic in character. This was more typical of the reticular zone cell type from the standpoint of morphology and routine histochemistry.

Group C: 97 Days - 206 Days (6 Specimens)

Subgroup C1: 97-100 days (2 specimens)

Capsule The capsule in this age group was observed to give rise to large numbers of small, uniformly spaced trabeculae which passed between the glomerular arches. These seemed to pass no further centripedially than the area where one might observe an intermediary zone. At their termination these trabeculae were observed to give off secondary fibers which supported the glomerular parenchyma. Cortical nodules were present as was a diffuse nebula of parenchymal-like cells, although they were less distinguishable, in the periadrenal fat.

Zona glomerulosa The parenchymal characteristics were very similar to those described in group B with the following exception. At the inner margin of the zona glomerulosa there was a marked "piling up" of cells which were laterally compressed and of columnar morphology. This produced a well demarcated zona intermedia.

Zona fasciculata The intermediary zone blended subtly with the outer fascicular cords which were arranged in a manner similar to those described in group B.

Zona reticularis This zone was well defined in these specimens. The zone was characterized by a rather abrupt histochemical change (by routine staining only) in these smaller parenchymal cells. These eosinophilic and highly granular cells were arranged in aggregates supported by a fine connective tissue network. Triple staining revealed that there were delicate connective tissue fibers at the cortical-medullary border.

Subgroup C2: 198-206 days (5 specimens)

Capsule There was a marked decrease in the cellular elements with a large accumulation of collagenous fibers. The division of the capsule into zones (i.e., an outer fibrous zone and inner cellular zone) as described for the earlier age groups was no longer easily recognizable. Large collagenous fibers continued into the capsular trabeculae. These trabeculae, for the most part, terminated by giving rise to a network of delicate fibers which passed on into the fasciculata to support the cells in that zone. Some of these fibers were seen to continue to the cortical-medullary border. Also, it was observed that at the inner margin of the zona glomerulosa some of the larger trabeculae communicated laterally with one another to, in effect, separate an arch or several arches of glomerular tissue from the immediately surrounding tissues. In some areas these large trabecular networks were observed to contain cells much like the capsular tissues of the glands examined in connection with the younger canine. There were several areas of cortical tissue nodules in the capsule, and evaginations of these nodules through the capsule were suggested. The periadrenal fat tissue contained some elements much as described in group B.

Zona glomerulosa This zone presented few differences from the description given above for group B, except those changes caused by the accumulation of a greater amount of connective tissue. The isolation of cellular aggregates was noted due to these collagenous elements and these also seemed to obscure any of the zona intermediary cells.

Zona fasciculata and reticularis Little difference was observed over the previous descriptions in group B. There was an accumulation of more connective tissue fibers along the cortical-medullary border.

Group D: 239-367 Days (12 Specimens)

The morphological changes became more gradual at this age and a greater range of chronological age is included herein. All zones were well defined and relatively easily delineated when compared with the younger adrenal.

Capsule

The most prominent capsular components were very coarse collagenous fibers. These were noted to continue centripetally into the zona glomerulosa as large trabeculae. In this zone they appeared to "isolate" bundles of glomerular parenchyma and then pass to the cortico-medullary border.

The intracapsular and pericapsular nodules were observed to increase in numbers and degree of involvement. These nodules were of sufficient size so that their overall morphology could be evaluated. In general, the nodules were intracapsular. In two dimensions these appeared, most generally, as encapsulated, parenchymal cell masses of varying size within the capsule. However, upon examination of several sections these were, in most cases, observed to have communication with the underlying parenchyma of the glomerulosa by a stock composed of a similar type cell.

The cells of the nodules and connecting stocks were, in morphological and routine histochemical respects, similar to the underlying glomerular parenchyma to which they were connected. In the larger nodules their arrangement was suggestive of arcades.

Zona glomerulosa

The zona glomerulosa was well defined and its relationship to the inner layer of the capsule was quite striking. At some points the trabeculae remained very cellular and subtly blended into the parenchyma. However, at the apex of the glomerular arcades the separation between the capsule and glomerulosa was quite distinct.

The zona intermedia appeared to be quite distinct in some specimens in this group and was present, in part, in all. The zona glomerulosa was noted to terminate here by blending into this zone, and in a similar manner the zona fasciculata appeared to arise here.

Zona fasciculata

In nearly all specimens the cuboidal spongiocyte was observed to be oriented in cords which radiated from the central part of the gland to the periphery.

The cells in the fasciculata were of two rather distinct types. Those fascicular cells in the outer one-half to two-thirds were of the typical spongiocyte type—large, cuboidal cells with a highly vacuolated cytoplasm and a nucleus similar to the other fascicular cells. Those cells in the inner fasciculata, occupying one-third to one-half of the fasciculata, were of a smaller size and had a less eosinophilic and less vacuolated cytoplasm. This morphological division into an inner and outer fasciculata was noted in those specimens approaching one year of age.

Zona reticularis

Another change observed in this group, versus the previous groups, was in the zona reticularis. The cytoplasm of these cells was highly eosinophilic and many nuclei were pyknotic. There was an apparent decrease in cell size as evidenced by an increase in reticular cell concentrations.

Group E: 1.2-4.2 Years (13 Specimens)

Capsule

The primary change noted was that of an increased prominence of fibrous elements with a decrease in prominence of the cellular capsule elements. The frequency of capsular trabeculae remained the same, but each was increased in magnitude, some to the extent of appearing as septae. Their ramifications at the zona intermedia and cortico-medullary border were similarly extensive.

Capsular, cortical cell nodules were frequently observed. Most of these were intracapsular and were connected to the underlying zona glomerulosa. There were some large encapsulated nodules which possessed an organization somewhat similar to the parent cortex. The peripheral cells were arranged in arcades and these blended with cells similar in most respects to the fasciculata cells. No zona intermedia or zona reticularis was noted in these nodules.

Cortex

There was a prominent zona intermedia in all glands of this age group as a narrow zone interposed between the glomerulosa and fasciculata.

The zona fasciculata was more clearly defined, by cell morphology and staining characteristics, into an inner and outer region.

The zona reticularis was well demarcated and H & E staining revealed a zone of cells which contained a smaller amount of cytoplasm and a smaller, more basophilic nucleus than cells of the zona fasciculata. Their cytoplasm was strongly eosinophilic and very granular. Other cells, closer to the cortico-medullary border, showed degenerative changes. These appeared to be retrogressive cell changes and typical of fatty degeneration. Vacuoles indicating large droplets of fat appeared in the cytoplasm. The nuclei in affected cells were seen to be in various stages of pyknosis. In scattered foci single cells or aggregates of cells appeared to have undergone fatty degeneration and only their membranous outlines remained. In other areas it appeared that this process had been followed by a capillary sinus expanding to fill the space once occupied by these cells. This gave a "punched out" appearance to the reticular zone tissue. These degenerative changes were seen with more frequency as age increased within the group.

Group F: 6.0-10.0 Years (9 Specimens)

The changes occurring in this age group primarily involved the cortical nodules and changes in the reticularis.

Capsule

Numerous intracapsular cortical nodules were noted. Some nodules of parenchymal cells were located outside of the main capsule but these were always surrounded by a thin boarder of collagenous fibers. These evaginated nodules were sometimes in an ovoid morphology and at other times spread out in a wide expanse following the curvature of the adrenal and, in this case, appeared to have "mushroomed" from the capsule when seen with the stock connecting it to the glomerulosa. The number of such areas was of lesser significance compared to the size of each evaginated cortical nodule.

Cortex

The cortex was composed of the three major zones and a zona intermedia as well as an inner and outer zona fasciculata.

The zona reticularis showed evidence of a more extensive fatty degeneration of its constituent cells. Large areas of degeneration could be seen and numerous dilated capillary sinuses permeated a randomly arranged mass of cells. In some areas these sinuses fused to form larger sinuses which ran parallel to, and at places, into the medulla.

The cortico-medullary border fibrous band showed evidence of having been penetrated by the parenchymal cells of the zona reticularis. The resulting moderate invagination of reticular cells into the medulla was, in the older members of this group, easily detected.

Group G: 10.4-13.6 Years (5 Specimens)

Capsule

A largely fibrous capsule was composed of generous bundles of collagenous fibers and proportionately few cellular elements. Dense and largely acellular trabeculae arose from the capsule and penetrated the glomerulosa between the arcades to the zona intermedia. Then lateral branching at this point produced, in some areas, an "isolation" of glomerular cell masses from the remainder of the cortex. Of the capsular components only the trabeculae appeared cellular. These relatively cellular trabeculae terminated at the zona intermedia.

The capsule contained numerous intracapsular cortical nodules but, more often, it was disrupted at intervals by evaginating masses of cortical tissue. The resulting large pericapsular nodules of cortical tissue occupied a large part of the capsular surface and equalled, in magnitude, a considerable percentage (estimated 10-15%) of the zona glomerulosa of the main gland. Some nodules were small, discrete bundles surrounded by large amounts of capsular fibers. Others were larger and of more complex internal structure with only a small amount of surrounding connective tissue. Still others were noted to be loosely applied in narrow bands on the outer surface of the capsule and extended, in this manner, for some distance from the site of evagination through the capsule.

Cortex

A generally well-defined zona intermedia separated the zona glomerulosa and zona fasciculata. The zona fasciculata was composed of outer and inner zones and the reticularis was quite prominent. The primary change noted was an involvement of extensive numbers of cells and cell aggregates in fatty degeneration. The reticular cords, often having deviated laterally, became separated from the neighboring cord by large capillary sinuses. Cells showing nuclear and cytoplasmic changes characteristic of fatty degeneration were distributed throughout the zona reticularis.

The cortico-medullary boundary of connective tissue was perforated by masses of nondegenerated reticular cells in numerous places. These cells invaginated into the medulla, were easily noted and, in some cases, these were located deep within the medulla.

Quantitative Results

Capsule (table II)

The absolute capsular thickness measurement readings were noted to increase progressively from birth to one-half year, with little variation in thickness from one-half year to 13.6 years.

Cortex (table II)

The three zones (glomerulosa, fasciculata and reticularis) were not distinguishable until two weeks of age. In nearly all ages the zona fasciculata was present in the greatest proportion (approximately 50%). The other two zones were approximately equal in extent. Generally the zona fasciculata showed some decrease with age. The zona reticularis appeared to increase slightly with advancing age and the zona glomerulosa varied little.

Cell counts from zona fasciculata (table III)

Data collected included 47 animals but for statistical analysis only specimens in the 0.6 year - 13.6 year range (total of 36) were used in an attempt to remove the influence of the early developmental changes of postnatal life.

At the beginning of this study visual inspection of the tissue specimens seemed to indicate that in older specimens there was an apparent increase in cells per unit area and for this reason this issue was submitted to statistical analysis. The least squares line was found to have a slope of 0.00064. However, due to very large variations about this regression line, the associated T was only 0.57, compared to a 5% T value of 2.02.

It was noted that essentially all of this high variation was associated with variation from dog to dog rather than cell count variation within a particular gland, since the latter standard deviation was estimated from the range data as equal to two, whereas the overall standard deviation about regression was estimated at 10.

DISCUSSION

Early Morphological Changes

The canine adrenal underwent some rather marked morphological changes in the first year of postnatal life. A very cellular capsule was characteristic of the newborn adrenal and the delineation of zonary boundaries within the cortex was not possible. These observations are in agreement with those of Randolph (1950), Zwemer, Wotton and Norkus (1938), Hill (1930), and Flint (1900).

Both large and small trabeculae were seen to arise from the capsule and penetrate into the zona glomerulosa. The larger of these trabeculae were highly cellular and their components blended with or, perhaps, became a part of the surrounding cortical parenchyma. It also seemed that the same capsular-cortical relationship existed at most areas of contact between the capsule and underlying cortex. Thus, early in postnatal life there was considerable morphological evidence indicating a continued migration of cells from the capsule into the cortex where they became a functional part of the cortex.

Most authors have not described a fetal cortex in the canine. However, Nicander (1952) described a narrow fetal cortex in the nearly full-term fetus which he noted to be present at birth and during the first week of postnatal life. He suggested that this zone was slowly transformed into the zona reticularis and possibly the inner zona fasciculata. However, in the present study (which included three specimens at birth but none of neonatal age) no morphological area or zone was detected in any of the specimens of any age which could be termed a fetal cortex.

Likewise, no morphologically distinct zona reticularis was evident, which is in agreement with the observation of those who have addressed themselves to this question.

The cortico-medullary boundary was indistinct, with numerous medullary cells being within the cortical parenchyma. This observation supports those of Randolph (1950) and Hill (1930).

Of special interest were the isolates of periadrenal fatty tissue in the area just outside of, and adjacent to, the capsule. These cells were richly pervaded by blood capillaries and are similar morphologically to the cortical parenchymal cells. Bachmann (1954) discussed at length the communication of the capsule with the environment. He referred to the work of Velican (1949) in which he proposed, in the human, a functional relationship between the cortex and the surrounding periadrenal fatty connective tissue by way of a shared circulatory network. He proposed that the periadrenal fat be included as a part of the "brown fat connective tissue" and, as such, a representative of "glandular fat." He noted the epitheloid character of the steatoblasts and an extensive vascularization of the area. These authors described the development of the capsule from fatty connective tissue. Postnatally they described accessory nodules of cortical tissue found in the periadrenal fat, without a surrounding capsule, but connected to the cortex through the capsule. Although the fatty connective tissue observed in this present study was not as extensive as that described for the human, it was similar in respect to cell composition and vascularization to that described for the human. Several nodules were observed to be closely associated with the periadrenal fat. No further evidence of these "spongiocyte-like" cells were observed in specimens beyond one year, in this study. It is interesting to note that, generally speaking, one year is the age at which sexual and physical maturity first approach the same magnitude. Velican (1949) suggested that the periadrenal fat and its extensive vascularization served to rapidly mobilize fat stores during the time of sexual activity.

By the end of the first postnatal month in the beagle the demarcation between the capsule and cortex was evident and the three zones of the cortex were well defined.

The capsule appeared to have an inner cellular and outer fibrous composition. The communication between the capsule and cortex seemed to be primarily at the trabeculae. The zona glomerulosa became elongated and the cells adopted a columnar morphology with a cylindrical, centrally located nucleus. These cells were arranged in cords which were disposed in arcades beneath the capsule.

The cuboidal cells of the zona fasciculata were arranged in radial cords which passed from the zona glomerulosa to the zona reticularis. These cells were paralleled, on at least two sides, by intervening capillaries which provided an easy access for these cells to a nutrient blood supply and a secretory channel.

The cords of fascicular cells approached the medulla and then deviated laterally at the cortico-medullary boarder. The organization into cords became disrupted and the sinus spaces between them increased in size. The cell cytoplasm became more eosinophilic and the cells were generally smaller and more concentrated in number. These were characteristically zona reticularis cells.

The medulla was composed of large polyhedral cells with a lightly basophilic cytoplasm and a centrally located vesicular nucleus. These cells were grouped in aggregates with large sinusoidal spaces between the aggregates. At the cortico-medullary boarder were fine collagenous fibers.

A similar histomorphological picture was characteristic of the first year. The morphology observed was similar in nearly all respects to those descriptions of the canine adrenal morphology by Selye and Stone (1950a), Bourne (1949), Nicander (1952), Randolph (1950), Smithcors (1964), Hill (1930), Vincent (1922), and Flint (1900).

Histomorphological Changes with Age

Connective tissue

Connective tissue changes were quite obvious with advancing age. The most easily noted change being within the capsule. Here the cellularity was gradually and progressively diminished and the area once occupied by cells was occupied by bundles of collagenous fibers. Loeb (1941) similarly observed, in mice, an accumulation of fibrous tissue in the capsule which destroyed a large amount of parenchymal cells. The capsule did not vary significantly in absolute thickness beyond six months of age. Quantification revealed that capsular thickness measurements increased progressively to 6 months but then little change was observed from 6 months to 13.6 years.

From the capsule, trabeculae penetrated to the boarder between the zona glomerulosa and zona fasciculata and then continued on as smaller elements through the cortex to the cortico-medullary border. Here they formed a band of collagenous fibers which separated the cortex and medulla. The trabeculae and related branches of fibers all increased in magnitude with advancing age. The most pronounced evidence of this was at the boarder of the zona glomerulosa and zona fasciculata in a narrow region called the zona intermedia. Here the laterally extending branches of the collagenous fibers joined with other adjoining fibers to form a rather thick band of fibrous connective tissue. In some areas there appeared to be "isolations" of glomerular cells from the remainder of the cortex. Although this was not an absolute isolation, the effective communication between the zona gomerulosa and cortex was definitely interrupted. A similar increase in relative magnitude of collagenous elements occurred at the cortico-medullary border and diffusely in areas of the zona reticularis. Dribben and Wolfe (1947) described, in the rat, a similar progressive increase in capsule thickness and of the collagenous fibers throughout the parenchyma of the gland. Blumenthal (1955) made similar observations in aging mice.

Cortical nodules

Extracortical nodules of cortical tissue were observed at 14 days and these increased in size and number throughout the age span investigated. The nodules were small and intracapsular in the younger ages but then they became pericapsular and much more extensive intracapsularly with advancing age. The cells of most nodules were of the glomerular cell type. However, in the older animals, the more massive nodules presented an arrangement of cells suggestive of glomerulosa and fascicular zoning.

These nodules were discrete and seemingly unrelated to the surrounding capsular elements, even when confined intracapsularly. Significant numbers of these were shown to have connections with the glomerulosa through the capsule by way of a narrow "stock" of cortical cells. In the middle aged animals the pericapsular nodules were encapsulated and rounded, but in the older animals some nodules were "mushroomed" over a considerable area of the capsule circumference.

Goodpasture (1918), in the dog, and Dribben and Wolfe (1947), in old rats, noted similar cortical nodules. Jayne (1957) described intracapsular and pericapsular nodules in the rat. In 1963 Jayne reported on a high incidence of nodular structures in mice which varied in size and arrangement of cells. Elias (1948) described intracapsular nodules in the horse, pig, goat, ox, and sheep.

Selye and Stone (1950b) referred to the "quite frequent" occurrence in man of capsular adenomas which occurred in, or just below, the capsule. Anderson (1961) described nodular hyperplasia in the human as usually involving "multiple, bilateral, small nodules of hyperplastic adrenal cortical tissue in the cortex, the capsule, or the periadrenal fat." He referred to the work of Smith, et al. (1959) in which they reported that one-third of all autopsies showed nodular hyperplasia. Commons and Callaway (1948) observed nodules greater than 3 mm. in 2.86 per cent of 7,437 autopsy specimens.

Regarding the significance of these nodules in the human, Selye and Stone (1950b) attributed their occurrence to "diseases of adaption." Anderson (1961) believed their occurrence to be "without apparent clinical significance." He noted that they were believed to increase with age.

Gruenwald (1946) suggested that the accessory cortical nodules were formed by pluripotential mesenchymal cells. Elias (1948), working with the horse, pig, goat, ox and sheep, hypothesized that these intracapsular nodules were formed in the capsule and eventually moved inwardly to fuse with the zona glomerulosa.

In the dog it was interesting to note that, morphologically, no "in between" stages of development were noted in these nodules or in the cells at the periphery of the nodules; all component cells appeared to be mature and independent of the surrounding capsule. Also of interest was that Schultz cholesteral and Oil Red O staining revealed that the nodules were composed of cells which stained positively for cholesterol and neutral lipids. These findings indicate a mature cell which is capable of participating in the metabolism of cholesterol and neutral lipids. This degree of differentiation suggests that these cells may not have arisen from intracapsular germinative elements but were, perhaps, evaginating glomeruolsa cells or, as Bachmann (1954) described them, "prolapsing" glomerular cells which, because of the spatial limitations imposed by the increase in connective tissue, were "being pushed" or "were pushing" through the capsular limiting boundary. As Jayne (1963) suggested, these cortical nodules could quite possibly compensate for a loss of functional parenchyma or an increased need for functional cortical cells. Gross (1964) pointed out that hyperplasia of this type is characteristic of tissues retaining their potential for mitotic proliferation.

Zona intermedia

Between the zona glomerulosa and zona fasciculata was a zone termed the zona intermedia. This narrow zone was a band of about 4-8 cells in thickness, the cells lying seemingly "compressed" between the two more major zones. The connective tissue was seen to increase in amount in this zone with advancing age. In the older specimens the amount of collagenous fibers were markedly increased as were the trabecular components. The larger cellular trabeculae seemed to terminate in this zone, that is, their cellular elements subtly became a part of this zone. The capsule and peripheral zona glomerulosa did not share cellular elements and the separation between them was distinct. Mitchell (1948) observed that there was no exchange between capsule and glomerulosa after the zona glomerulosa differentiated. It seems significant that the trabeculae communicating with the zona intermedia may be the only source of communication between the germinative layers of the capsule and the cortex. Perhaps, when needed, these trabeculae might supply new cortical replacement cells.

Brenner (1963) showed, by labelling newly divided cells with tritiated thymidine, that most mitotic activity occurred in the region of the inner glomerulosa and outer fasciculata. The label was over a period of a few weeks traced through the cortex and then seen to disappear from the reticularis. Hoerr (1931) suggested migration of cells within the capsule and a reproduction by cells dividing at the glomerular-fascicular border. He noted that the stress of old age enhanced this rate of turnover. Deane and Greep (1946) suggested that cells of the subglomerulosal layer move through the cortex but that glomerular cells do not.

The question arises as to what may be the source of new cortical cells if one assumes the theory of continual replacement and migration through the cortex. It is of interest that the center of the "mitotic centers" in the cortex, mentioned above as the inner glomerulosa and outer fasciculata, is the zona intermedia. Deane and Greep (1946) noted an absence of mitotic activity in the zona intermedia area. In the canine, an evaluation of the mitotic index of the zona intermedia may be indicated to determine if, rather than an intermediate or transitory zone, it might serve as the germinative layer in the older animal. It could supply glomerular parenchymal elements and at the same time fascicular cortical cells.

Zona fasciculata

Beginning at one year the zona fasciculata was seen to be divided into an outer and inner zone based on cell size and differences in cytoplasmic staining. The outer zone was composed of larger cells separated by narrower, more compressed capillary sinuses. The cytoplasm was very vacuolated and light staining. The inner zone was composed of eosinophilic cells which were then separated by larger sinuses. It is interesting to note that Carr (1961) showed that the poststimulated fascicular zone cell appeared to resemble closely the cells typical of the zona reticularis.

Reticularis

The zona reticularis, after one year, showed evidence of fatty metaplasia. This was minimal at one year and became more marked with advancing age. As a result of these changes the spaces were often occupied by dilated capillary sinuses. Under magnification these gave a "punched out" appearance.

Yoffey (1953) stressed the term "normal" and suggested that fatty metaplasia may reflect the fact that the reticularis is, of the three primary zones, the one most susceptible to change induced by stimuli. Jayne (1957), in the rat, noted extensive degenerative changes with increasing age.

Cortico-medullary boarder

There was an invagination of reticular cell elements through the collagenous band at the cortico-medullary boarder and these cells occupied positions within the medulla. In some cases these were connected to the reticular parenchyma and, in other instances, they occurred as isolated cell masses.

Cortical hyperplasia with increasing age

A pilot study was conducted to determine if, due to the "stresses of increased age," the zones were increasing or decreasing in overall percentage composition and if any changes were due to a hypertrophy, hyperplasia or atrophy of cellular components. The zonary measurements are tabulated in Table II. The overall mean percentage values for 6 months to 13.6 years are:

Zona glomerulosa = 27%
Zona fasciculata = 50%
Zona reticularis = 23%

Baker (1937) reported a 24% figure for the zona glomerulosa in six specimens studied.

The cell counts per unit area in the zona fasciculata showed a relatively small variance in sampling within the individuals, but a large variance between individuals. When one considers the dynamic nature of the endocrine system and the interrelationship of all the components of the system, the variance from individual to individual is actually what one might expect.

Based on this limited analysis one would conclude that the cell concentrations per unit area in the zona fasciculata do not change significantly with age. This indicates that in adulthood growth of the functional parenchymal zones may be accomplished by adding new cells to these areas rather than by an increase in cell size.

Blood vessels

The blood vessels of the capsule, cortex and medulla were examined for possible atherosclerotic changes, but the slides studied to date revealed no evidence of plaque formation. The integrity of the intrinsic circulatory system was normal in morphology. Korenchevsky (1961) emphasized the possible importance of these lesions in the degenerative changes in the cortex.

Role of the Canine Adrenal Gland in Aging

To properly evaluate the morphological changes occurring with age in the canine adrenal as they relate to a primary or secondary role in the aging process, the following criteria have been used (Strehler, 1962).

Universality. The major changes observed were manifested in some degree in all of the older animals studied.

Intrinsicality. On this criterion one encounters difficulty in defining the stress factors which cause an imbalance of the homeostatic mechanism; are these extrinsic or intrinsic or both? For general hypertrophy, hyperplasia and metaplasia occur in response to many stimuli in what is termed the general-adaptation-syndrome (Selye and Stone, 1950a).

Progressiveness. Examination of the results indicates several gradual processes were manifested at the organ level.

Deleteriousness. It appears that some changes, such as the connective tissue accumulation and degenerative cortical changes, do serve to reduce the functionability of the gland. However, other changes, such as the cortical cell nodules, are secondary in nature and actually may bring about an improved functionability. Thus, as Blumenthal (1955) discussed, when considering the regressive changes in an endocrine gland, one must search also for compensitory changes.

As Selye and Stone (1950a) emphasized, the adrenal exhibits generalized nonspecific responses as well as very specific responses to a wide variety of stimuli. He concluded that this implies that "either the pituitary produces a number of different corticotrophins" or "that the same pituitary trophic principle exerts different actions, depending on the simultaneous presence of other hormones (e.g., steroids)."

Solomon and Shock (1950) reported that in aged humans there was no impairment of adrenal cortical ability to secrete 11-17-oxysteroid group hormones when stimulated by ACTH.

Rothenbacher and Shigley (1966) reporting a clinical case of adrenocortical apoplexy in a 12-year-old mongrel dog. They suggested that adrenal cortical apoplexy be considered an independent cause of death.

Korenchevsky (1961) pointed out that the adrenals have rarely been mentioned as a causative factor of aging. Hickler (1962) stressed the lack of evidence to show that an alteration in adrenal function is significant or primary as a factor in aging.

The observations in this study plus those of others mentioned herein, when one also considers the apparent good health of the animals studied, lead one to conclude that perhaps only a secondary role may be played by the adrenal in the aging process.

SUMMARY

1. Adrenal glands from 56 purebred Beagle dogs ranging in age from birth to 13.6 years were included in this study. An evaluation of quantitative histomorphological changes with advancing age has been presented.
2. Rather marked morphological changes were observed in the first year of postnatal life. In this age period the capsule, zona glomerulosa, zona fasciculata, zona reticularis and medulla became morphologically distinct.
3. No morphological evidence of a fetal cortex was observed in any of the specimens included in this study. Likewise, no zona reticularis was discernible until two weeks of age.
4. The periadrenal fatty tissues were highly vascularized and many pericapsular, cortical cell nodules, which were lacking a distinct limiting capsule, were embedded within the periadrenal fat.
5. Much morphological evidence indicative of possible exchange of cellular components between the capsule and zona glomerulosa was observed until 6 months of age. After 6 months these areas were confined to the cellular trabeculae. These observations would support the idea that the capsule is a germinative center, serving as the origin of cortical parenchymal components in early life.
6. Connective tissue changes were quite apparent with advancing age. The collagenous fibers were observed to increase in size and numbers with increased age. These changes were observed in the capsule, in the capsular trabeculae, at the cortico-medullary border and in the parenchymal supporting elements of the cortex and medulla.

7. Extracortical parenchymal nodules were observed in the 14 day-old specimens and these increased in both size and numbers with increased age. These nodules of cortical cells were seen both within and outside the capsule. The nodules were discrete and significant numbers of these could be shown to have connections through the capsule with the glomerulosa.
8. All cells within the extracortical nodules gave positive reactions for cholesterol and neutral lipids. This was suggestive of a certain degree of differentiation among these cells as opposed to their being newly formed undifferentiated cells arising from germinative elements within the capsule. The conclusion drawn was that these nodules may be differentiated cortical nodules evaginating through the capsule, rather than moving inwardly from the capsule to the cortex.
9. A well-defined zona intermedia was observed beginning at one month of age between the zona glomerulosa and zona fasciculata. Capsular trabeculae were observed to, in large part, terminate in this zone with their cellular contents joining the compact, 6-8 cell thickness of this zone. It appeared that this zona intermedia might serve as a germinative zone in the older animals.
10. A morphological division based on differences in cell size and cytoplasmic staining was apparent in the zona fasciculata. On this basis the zone can be divided into an inner and outer zona fasciculata.
11. Fatty metaplasia was observed in increasing amounts in the zona reticularis with advancing age. In the specimens 4.2 years of age and older, fatty degeneration was frequently observed.

12. Limited quantitative measurements revealed the average zonary widths for the 36 specimens studied (ranging in age from 6 months to 13.6 years) to be: zona glomerulosa 27%, zona fasciculata 50% and zona reticularis 23% for all animals. Insufficient numbers of male animals at the older ages in this study limited the value of comparison on the basis of sex.
13. Cell counts per unit area in the zona fasciculata showed that in the older animals growth of the functional parenchyma occurred primarily by hyperplasia.
14. Examination of the intrinsic circulatory system has revealed no evidence of plaque formation. However, this evaluation should be continued to search for more subtle blood vascular changes which might serve as primary factors in producing adrenal changes with age.
15. In this work the changes with age appeared progressive and universal in the specimens studied. However, the intrinsicality and deleteriousness of some changes must be evaluated further. These further studies may give support to the conclusion that, in large part, the histomorphological changes occurring with age in the canine adrenal are of a secondary versus a primary nature.

BIBLIOGRAPHY

Alpert, L. K. 1931. The innervation of the suprarenal glands. Anatomical Record 50:221-233.

Anderson, W. A. D. 1961. Primary hyperplasia and neoplasia of the adrenal cortex. In Moon, H. D., ed. The adrenal cortex. pp. 220-238. New York, New York, Paul B. Hoeber, Inc.

Andrew, Warren. 1952. Cellular changes with age. Springfield, Illinois, Charles C. Thomas.

Armed Forces Institute of Pathology. 1960. Manual of histologic and special staining techniques. 2nd ed. New York, New York, McGraw-Hill Book Co., Inc.

Bachmann, R. 1954. Die Nebenniere. Handbuch der Mikroskopischen Anatomie des Menschen 5:1-952.

Baillif, R. N. and Baker, Dan Dysart. 1938. The role of the capsule in suprarenal regeneration. Anatomical Record 70, Supplement 3:87.

Baker, Dan Dysart. 1937. Studies of the suprarenal glands of dogs. I. Comparison of the weights of suprarenal glands of mature and immature male and female dogs. American Journal of Anatomy 60:231-252.

Bell, J. Thomas. 1959. Polyoxyethylene sorbitan monopalmitate (Tween 40) as a vehicle for oil red O fat stain. Stain Technology 34:219-221.

Bennett, H. Stanley. 1940. The life history and secretion of the cells of the adrenal cortex of the cat. American Journal of Anatomy 67:151-227.

Blanchard, R. 1882. Sur l'historie de la decouverte de la capsule surrenale. Comptes Rrendus Societe Biologie Paris 34:325-327. Original available but not translated; cited in Bourne, Geoffery H. 1949. The mammalian adrenal gland. p. 2. London, England, Oxford University Press.

Blane, H. W. and Gregs, R. O. 1946. A morphological and histochemical study of the rat's adrenal cortex after hypophysectomy, with comments on the liver. American Journal of Anatomy 79:117-146.

Blumenthal, H. T. 1945. Aging processes in the endocrine glands of the guinea pig. I. The influence of age, sex, and pregnancy on the mitotic activity and the histologic structure of the thyroid, parathyroid, and adrenal glands. Archives of Pathology 40:264-269.

Blumenthal, N. T. 1955. Aging processes in the endocrine glands of various strains of normal mice: relationship of hypophyseal activity to aging changes in other endocrine glands. Journal of Gerontology 10:253-267.

Bourne, G. H. 1949. The mammalian adrenal gland. London, England, Oxford University Press.

Bourne, G. H., ed. 1961. Structural aspects of aging. New York, New York, Hafner Publishing Co.

Bourne, Geoffrey H. 1961. Comparative anatomy and embryology of the adrenal glands. In Moon, H. D., ed. The adrenal cortex. 1-22. New York, Paul B. Hoeber, Inc.

Brenner, R. M. 1963. Radioautographic studies with tritiated thymidine of cell migration in the mouse adrenal after carbon tetrachloride stress. American Journal of Anatomy 112:81-96.

Cammermeyer, Jan. 1963. Cytological manifestations of aging in rabbit and chinchilla brains. Journal of Gerontology 18:41-54.

Carlson, A. J. 1942. The thyroid, pancreatic islets, parathyroids, adrenals, thymus and pituitary. In Cowdry, E. V., ed. Problems of ageing. 2nd ed. pp. 412-445. Baltimore, Maryland, Williams and Wilkins Co.

Carr, I. 1961. The ultrastructure of the human adrenal cortex before and after stimulation with ACTH. Journal of Pathology and Bacteriology 81:101-106.

Chalkley, H. W. 1943. Method for the quantitative morphologic analysis of tissues. National Cancer Institute Journal 4:47-53.

Comfort, Alex. 1964. Ageing: the biology of senescence. London, England, Routledge and Kegan Paul.

Commons, R. R. and Callaway, C. P. 1948. Adenomas of the adrenal cortex. Archives of Internal Medicine 81:37-41.

Cooper, Eugenia, R. A. 1925. The histology of the more important human endocrine organs of various ages. New York, New York, Oxford University Press.

Cowdry, E. V. 1942. Ageing of individual cells. In Cowdry, ed. Problems of ageing. 2nd ed. pp. 626-663. Baltimore, Maryland, Williams and Wilkins Co.

Crossman, G. A. 1937. A modification of Mallory's connective tissue stain with a discussion of principles involved. Anatomical Record 69:33-38.

Deane, H. W. and Greep, O. R. 1946. A morphological and histochemical study of the rat's adrenal cortex after hypophysectomy, with comments on the liver. American Journal of Anatomy 79:117-146.

de Groot, Jack and Fortier, Claude. 1959. Quantitative and histological aspects of adrenal cortical regneration in the male albino rat. Anatomical Record 133:565-578.

Della-Chiaje. 1837. Esistenza delle glandule renale di Batrachi et di Pesci. Original not available; cited by Bourne, Geoffery H. 1949. The mammalian adrenal gland. p. 1. London, England, Oxford University Press.

Dribben, I. S. and Wolfe, J. M. 1947. Structural changes in the connective tissue of the adrenal glands of female rats associated with advancing age. Anatomical Record 98:557-585.

Ecker, Alexander. 1846. Der feinere Bau der Nebennieren beim Menschen und den vier Wirbelthierclassen. Braunschweig. Original not available; cited by Bourne, Geoffery H. 1949. The mammalian adrenal gland. p. 5. London, England, Oxford University Press.

Elias, Hans. 1948. Growth of the adrenal cortex in domesticated Ungulata. American Journal of Veterinary Research 9:173-189.

Elliott, T. R. and Armour, R. G. 1911. The development of the cortex in the human suprarenal gland and its condition in hemicephaly. Journal of Pathology 15:481-488.

Eustachius, Barthotomaeus. 1563. De renibus libellus. Venetiis. (Auch in: Opusc. Anat. Venet. 1564, in Edit. opusc. Anat. L. B. 1707.) Original not available; cited by Bourne, Geoffery H. 1949. The mammalian adrenal gland. p. 1. London, England, Oxford University Press.

Findlay, G. M. 1920. The pigments of the adrenals. Journal of Pathology 23:482-489.

Flint, A. 1900. The blood vessels, angiogenesis, organogenesis, reticulum and histology of the adrenal. Johns Hopkins Hospital Bulletin 9:153-230.

Getty, Robert. 1949. Histocytological studies on normal bovine livers and on bovine livers exhibiting a focal hepatitis and telangiectasis. Unpublished Ph.D. thesis. Ames, Iowa, Library, Iowa State University of Science and Technology.

Getty, Robert. 1962. Gerontologic studies in domestic animals: their implications and applications. American Medical Association Journal 140:1323-1324.

Getty, Robert. 1963. Gerontology in animals. World Veterinary Congress, 17th, Hannover, 1963, Proceedings 1:157-161.

Getty, Robert. 1965. Occurrence and distribution of spontaneous vascular lesions in the dog from birth to senescence. (Abstract) Gerontologist 5:20.

Goldzieher, M. A. 1944. The adrenal glands in health and disease. Philadelphia, Pennsylvania, F. A. Davis Co.

Goodpasture, E. W. 1918. An anatomical study of senescence in dogs. Journal of Medical Research 38:127-189.

Graham, G. S. 1916. Toxic lesions of the adrenal gland and their repair. Journal of Medical Research 34:241-262.

Gross, Richard. 1964. Adaptive growth. New York, New York, Academic Press.

Gruenwald, Peter. 1942. Common traits in development and structure of the organs originating from the coelomic wall. Journal of Morphology 70:353-387.

Gruenwald, Peter. 1946. Embryonic and postnatal development of the adrenal cortex, particularly the zona glomerulosa and accessory nodules. Anatomical Record 95:391-421.

Gruenwald, Peter and Konikov, William M. 1944. Cell replacement and its relation to the zona glomerulosa in the adrenal cortex of mammals. Anatomical Record 89:1-21.

Haensly, William E. and Getty, Robert. 1965. Age changes in the weight of the adrenal glands of the dog. Journal of Gerontology 20:544-547.

Hartman, F. A. and Brownell, K. A. 1949. The adrenal gland. London, England, Kimpton.

Hickler, R. B. 1962. The adrenals and aging. American Geriatric Society Journal 10:22-25.

Hill, W. C. Osman. 1930. Observations on the growth of the suprarenal cortex. Journal of Anatomy 64:477-479.

Hoerr, Norman Louis. 1931. The cells of the suprarenal cortex in the guinea pig: their reaction to injury and replacement. American Journal of Anatomy 48:139-198.

Howard-Miller, Evelyn. 1938. The representation of the adrenal X-zone in rats, in the light of observations on X-zone variability in mice. American Journal of Anatomy 62:351-375.

Jayne, E. P. 1953. Cytology of the adrenal gland of the rat at different ages. Anatomical Record 115:459-483.

Jayne, E. P. 1957. Histochemical and degenerative changes in the adrenal cortex of the rat with age. Journal of Gerontology 12:1-8.

Jayne, E. P. 1963. A histo-cytologic study of the adrenal cortex in mice as influenced by strain, sex, and age. Journal of Gerontology 18:227-234.

Karsner, H. T. 1950. Tumors of the adrenal. In Atlas of tumor pathology, Sect. 8, Fascide 29. Washington, D. C., Armed Forces Institute of Pathology.

Keene, M. F. Lucas and Hewer, E. E. 1927. Observations on the development of the human suprarenal gland. Journal of Anatomy 61:302-324.

Korenchevsky, V. 1961. Physiological and pathological ageing. Karger, Basle.

Lansing, A. I., ed. 1952. Problems of ageing. Baltimore, Williams and Wilkins Co.

Loeb, R. F. 1941. Adrenal cortex insufficiency. American Medical Association Journal 116:2495.

Meyers, M. W. and Charipper, H. A. 1956. A histological and cytological study of the adrenal gland of the golden hamster (Cricetus auratus) in relation to age. Anatomical Record 124:1-25.

Mitchell, R. M. 1948. Histological changes and mitotic activity in the rat adrenal during postnatal development. Anatomical Record 101:161-185.

Nicander, Lennart. 1952. Histological and histochemical studies on the adrenal cortex of domestic and laboratory animals. Acta Anatomica 14, Supplement 16:3-98.

Nichols, John and Hennigar, Gordon. 1946. Effects of pulmonary hypertension on adrenal and kidneys of dogs infected with heart worms (Dirofilaria immitis). Laboratory Investigation 13:800-808.

Randolph, K. H. 1950. Growth changes in the adrenal gland of the dog from birth to two years of age. Unpublished Masters thesis. Ames, Iowa, Library, Iowa State University of Science and Technology.

Randolph, K. H., Getty, R., Foust, H. L. and Ramsey, F. K. 1951. Growth changes in the adrenal gland of the dog from birth to two years of age. Journal of Gerontology 6:138-139.

Rogoff, J. M. and Stewart, G. N. 1926. Studies on adrenal insufficiency; control animals not subjected to any treatment. American Journal of Physiology 78:683-710.

Rogoff, J. M. and Stewart, G. N. 1928. Studies on adrenal insufficiency; the influence of adrenal extracts on the survival period of adrenalectomized dogs. American Journal of Physiology 84:660-674.

Rothenbacher, H. and Shigley, R. F. 1966. Adrenocortical apoplexy in a dog. Journal of the American Veterinary Medical Association 149:406-411.

Selye, Hans and Stone, Helen. 1950a. On the experimental morphology of the adrenal cortex. Springfield, Charles C. Thomas.

Selye, Hans and Stone, Helen. 1950b. Hormonally induced metaplasia of adrenal into myelaid tissue. American Journal of Pathology 26:211.

Smith, E. B., Beamer, P. R., Vellios, F., and Schulz, D. M. 1959. Principles of human pathology. New York, Oxford University Press.

Smith, E. M., Calhoun, M. L. and Reineke, E. P. 1953. The histology of the anterior pituitary, thyroid, and adrenal of thyroid-stimulated purebred English bulldogs. Anatomical Record 117:221-240.

Smithcors, J. F. 1964. The endocrine system. In Miller, Malcolm E., Christensen, George C., and Evans, Howard E. pp. 807-836. Philadelphia, Pennsylvania, W. B. Saunders Co.

Solomon, D. H. and Shock, N. W. 1950. Studies of the adrenal cortical and anterior pituitary function in elderly men. Journal of Gerontology 5:302-313.

Strehler, Bernard L. 1962. Time, cells, and aging. New York, New York, Academic Press.

Strehler, B. L. 1964. Advances in gerontological research. New York, Academic Press.

Velican, Constantine. 1949. Observations Morphofonctionnelles sur la corticosurrenale humaine. Folia endocrinologica. Pisa 2:99-118. Original not available; cited in Bachmann, R. 1954. Die Nebenniere. Handbuch der Mikroskopischen Anatomie des Menschen 5:160.

Vincent, Swale. 1922. Internal secretion and the ductless glands. London, England, E. Arnold Co.

Weber, A. F., Phillips, M. G., and Bell, J. T. 1956. An improved method for the Schultz cholesterol test. Journal of Histochemistry and Cytochemistry 4:308-309.

Winslow, J. 1732. Exposition anatomique de la structure du corps humain. 4Bde. Paris. Original not available; cited by Bourne, Geoffery, H. 1949. The mammalian adrenal gland. p. 4. London, England, Oxford University Press.

Wotton, R. M. and Zwemer, R. L. 1943. A study of the cytogenesis of corticoadrenal cells in the cat. Anatomical Record 86:409-416.

Yeakel, Eleanor H. 1946. Changes with age in the adrenal gland of Wistar albino and gray Norway rats. Anatomical Record 96:525.

Yoffey, J. M. 1953. The suprarenal cortex: the structural background. Symposium of the Colston Research Society Proceedings 5:31-38.

Zwemer, Raymund L., Wotton, R. M. and Norkus, M. G. 1938. A study of corticoadrenal cells. Anatomical Record 72:249-263.

ACKNOWLEDGMENTS

The author expresses sincere appreciation to Dr. Robert Getty for his counsel, encouragement and constructive criticism, rendered not only during the course of the investigation and preparation of the thesis, but as a mentor during the author's professional education, graduate education and research training.

To Dr. J. F. Munnell and Dr. L. I. Saar the author expresses gratitude for constructive criticism and the stimulus given to this fellow traveler.

The author expresses sincere appreciation to Dr. H. T. David for statistical advice and counsel.

The author is grateful to Dr. D. J. Hillmann for providing excellent photographic assistance and valuable cooperation.

To Mr. R. N. Lanz the author expresses special thanks for the competent technical assistance rendered in preparation of the microscopic specimens.

Lastly, the author expresses sincere appreciation to his wife, Patricia, for her patience and understanding, and to David, Tom and John for their cheerful interest in all things being done.

This investigator was supported by research fellowships, numbers HD-28,048-01 and HD-28,048-02, from the National Institute of Child Health and Human Development, United States Public Health Service, and the investigation was supported in part by Public Health Service Research Grant numbers HE-04487 and HD-0041 from the National Institutes of Health; General Foods Corporation, Battle Creek, Michigan; and Fort Dodge Laboratories, Inc., Fort Dodge, Iowa.

APPENDIX A. TABLES

Table 1. Age and sex of animals studied

Identification Number	Breed	Sex	Age in Days	Age in Years
7	Beagle	M	8 hours	Birth
8	Beagle	F	8 hours	Birth
9	Beagle	F	8 hours	Birth
52	Beagle	M	4	0.01
10	Beagle	M	9	0.02
34	Beagle	M	14	0.04
35	Beagle	F	14	0.04
45	Beagle	M	28	0.08
46	Beagle	F	28	0.08
28	Beagle	M	36	0.1
29	Beagle	F	36	0.1
47	Beagle	M	57	0.2
26	Beagle	M	97	0.3
27	Beagle	M	100	0.3
66	Beagle	F	198	0.5
59	Beagle	F	205	0.6
60	Beagle	M	205	0.6
61	Beagle	F	206	0.6
48	Beagle	F	239	0.7
49	Beagle	F	247	0.7
21	Beagle	M	252	0.7
22	Beagle	M	281	0.8
67	Beagle	F	283	0.8
53	Beagle	M	302	0.8
55	Beagle	M	336	0.9
54	Beagle	M	364	1.0
56	Beagle	M	365	1.0
57	Beagle	M	365	1.0
58	Beagle	M	365	1.0
62	Beagle	F	367	1.0
37	Beagle	M	437	1.2
41	Beagle	F	626	1.7
12	Beagle	F	648	1.8
13	Beagle	F	699	1.9
11	Beagle	F	709	1.9
24	Beagle	F	826	2.3
25	Beagle	F	827	2.3
23	Beagle	M	962	2.6
16	Beagle	M	1214	3.3
20	Beagle	M	1226	3.4
36	Beagle	M	1245	3.4
65	Beagle	F	1304	3.6
51	Beagle	F	1520	4.2

Table 1 (Continued)

Identification Number	Breed	Sex	Age in Days	Age in Years
18	Beagle	F	2192	6.0
30	Beagle	F	2739	7.5
44	Beagle	F	2829	7.8
43	Beagle	F	2830	7.8
33	Beagle	F	3317	9.1
63	Beagle	M	3355	9.1
19	Beagle	M	3366	9.2
64	Beagle	F	3667	10.0
15	Beagle	F	3791	10.4
31	Beagle	F	4520	12.4
17	Beagle	F	4701	12.9
32	Beagle	M	4952	13.6
14	Beagle	F	4980	13.6

Table 2. Biometric analysis of 47 specimens — capsule and zone measurements

	Beagle Number	Age in Days	Sex	Capsule Thickness in u (Average 4 Measurements)	Average for Age Group	% Volume Cortex Occupied by Zona Glomerulosa	Average for Age Group	% Volume Cortex Occupied by Zona Fasciculata	Average for Age Group	% Volume Cortex Occupied by Zona Reticularis	Average for Age Group
Group A	7	Birth	M	0.08		----*		----		----	
	8	Birth	F	0.05		----		----		----	
	9	Birth	F	0.04	0.057	----	----	----	----	----	----
Group B	10	9	M	0.06		----		----		----	
	34	14	M	0.95		30.1		69.9		0.0	
	35	14	F	0.52		14.8		85.2		0.0	
	45	28	M	0.77		19.3		80.7		0.0	
	46	28	F	1.00		18.2		67.8		14.0	
	28	36	M	0.45		26.9		64.0		9.1	
	47	57	M	1.00	0.68	23.1	22.1	44.8	68.7	32.1	9.2
Group C	27	100	M	0.94		46.7		33.8		19.6	
	66	198	F	1.60		38.2		34.0		27.8	
	59	205	F	1.10		30.2		47.4		22.4	
	60	205	M	1.30		31.0		45.7		23.3	
	61	206	F	0.93	1.17	29.4	35.1	55.3	43.2	15.3	21.7
Group D	48	239	F	1.00		32.4		47.2		20.4	
	49	247	F	1.10		14.8		61.8		23.4	
	21	252	M	1.10		27.3		60.1		12.6	
	22	281	M	0.76		22.2		60.7		17.2	
	53	302	M	0.90		29.9		55.2		14.9	
	55	336	M	1.20		32.3		52.6		15.2	
	54	364	M	0.87		21.8		51.0		27.2	
	56	365	M	1.10		25.2		53.0		21.8	
	57	365	M	1.00		26.2		60.3		13.5	
	58	365	M	1.00		27.7		54.5		17.8	
	62	367	F	1.30	1.03	23.4	25.7	36.8	53.9	39.8	20.3

---

*--- signifies zone not delineated

Table 2 (Continued)

	Beagle Number	Age in Days	Sex	Capsule Thickness in u (Average 4 Measurements)	Average for Age Group	% Volume Cortex Occupied by Zona Glomerulosa	Average for Age Group	% Volume Cortex Occupied by Zona Fasciculata	Average for Age Group	% Volume Cortex Occupied by Zona Reticularis	Average for Age Group
Group E	41	626	F	0.98		41.4		46.0		12.6	
	12	648	F	1.10		20.9		58.9		20.2	
	13	699	F	0.97		40.7		45.9		13.4	
	11	709	F	0.64		21.1		65.0		13.9	
	24	826	F	0.80		27.5		53.2		19.3	
	25	827	F	1.10		24.7		60.6		14.7	
	23	962	M	1.50		24.8		54.7		20.4	
	16	1214	M	0.71		32.4		46.8		20.8	
	36	1245	M	1.50		26.9		60.7		12.4	
	65	1304	F	1.70		30.6		32.4		37.0	
	51	1520	F	0.93	1.08	24.5	28.7	40.0	51.3	35.6	20.0
Group F	18	2192	F	0.88		16.8		46.4		36.7	
	44	2829	F	1.20		25.4		38.8		35.7	
	43	2830	F	0.76		19.3		49.2		31.5	
	33	3317	F	1.20		33.2		44.2		22.6	
	63	3355	M	1.30		20.5		40.6		38.9	
	64	3667	F	1.40	1.12	30.7	24.3	44.9	44.0	24.4	31.6
Group G	15	3791	F	0.96		26.1		55.9		18.0	
	17	4701	F	1.20		19.1		48.0		32.8	
	32	4952	M	1.50		20.2		33.2		46.6	
	14	4980	F	0.77	1.11	24.0	22.4	43.1	45.0	32.8	32.6

Table 3. Biometric analysis of 47 specimens — cells per unit area

	Beagle Number	Age in Days	Cells per Unit Area of Zona Fasciculata (Average of 10 Readings)	Average for Age Group	Range of 10 Readings for the Individual Animal	Average Range for Age Group
Group A	7	Birth M	80.5		49	
	8	Birth F	74.8		56	
	9	Birth F	64.9	73.4	28	44
Group B	10	9 M	82.8		20	
	34	14 M	75.9		33	
	35	14 F	78.2		24	
	45	28 M	70.7		27	
	46	28 F	63.6		34	
	28	36 M	54.7		28	
	47	57 M	51.2	68.2	19	25
Group C	27	100 M	48.6		20	
	66	198 F	57.3		20	
	59	205 F	47.9		20	
	60	205 M	61.2		18	
	61	206 F	60.9	55.2	28	22
Group D	48	239 F	55.3		17	
	49	247 F	59.8		21	
	21	252 M	38.3		16	
	22	281 M	56.3		19	
	53	302 M	71.2		27	
	55	336 M	68.1		21	
	54	364 M	52.6		30	
	56	365 M	44.5		23	
	57	365 M	61.9		26	
	58	365 M	64.5		21	
	62	367 F	69.3	58.3	45	24

Table 3 (Continued)

	Beagle Number	Age in Days		Cells per Unit Area of Zona Fasciculata (Average of 10 Readings)	Average for Age Group	Range of 10 Readings for the Individual Animal	Average Range for Age Group
Group E	41	626	F	63.7		25	
	12	648	F	60.7		15	
	13	699	F	62.0		13	
	11	709	F	60.3		19	
	24	826	F	46.0		29	
	25	827	F	46.6		23	
	23	962	M	45.5		15	
	16	1214	M	68.8		31	
	36	1245	M	74.0		8	
	65	1304	F	42.5		11	
	51	1520	F	67.7	58.0	23	19
Group F	18	2192	F	47.0		22	
	44	2829	F	67.2		17	
	43	2830	F	82.0		28	
	33	3317	F	53.0		18	
	63	3355	M	72.0		16	
	64	3667	F	58.8	63.3	25	18
Group G	15	3791	F	56.7		17	
	17	4701	F	53.2		33	
	32	4952	M	52.5		15	
	14	4930	F	64.6	56.8	39	24

APPENDIX B. FIGURES

Please note that because the size relationships have been stressed in this study, the magnification listed on all photographic reproductions is the actual total magnification. This includes the microscopic, negative and print magnification factors in each case.

Fig. 1. Cross section of an adrenal gland from an 8-hour old female canine (B9). Capsule (Ca) bounded peripherally by periadrenal fatty connective tissue. Cortex (C) showing little zone development. Medulla (M) contains large central vein. Large nerve bundles (N) often seen closely applied to capsule. Stained with Mallory's triple. Magnification X 28.

Fig. 2. Cross section of an adrenal gland from a 28-day old female canine (B46). Large nerve bundles (N) in periadrenal area. Zona glomerulosa (G) showing evidence of arcade formation. Fasciculata (F) and the zona reticularis (R) which is just forming. The medulla (M). Stained with Mallory's triple. Magnification X 16.

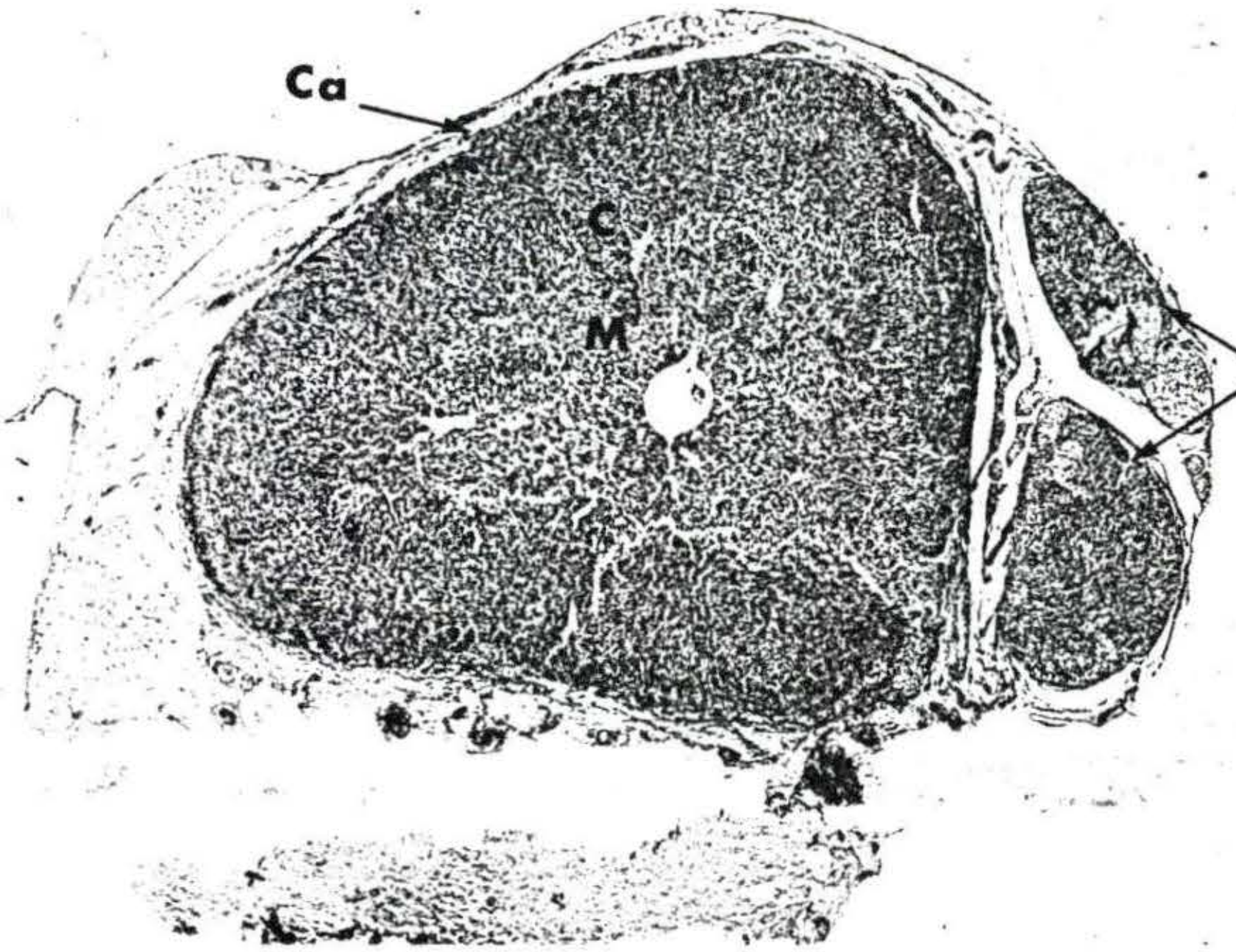
Ca
C
M
N

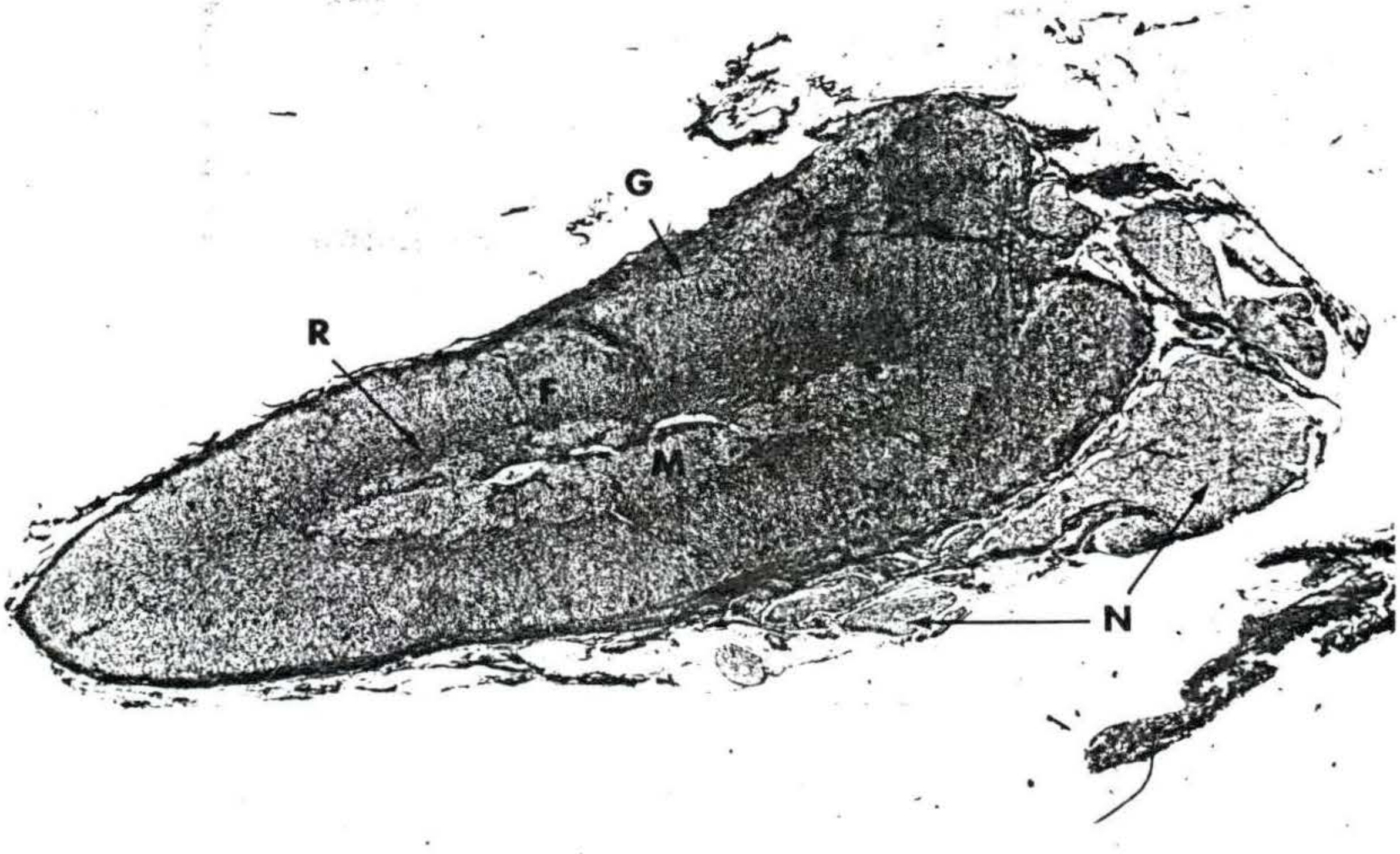
G
R
F
M
N
N

Fig. 3. Overall view of cortex of adrenal gland from an 8-hour old female canine (B9). Note areas of communication by direct apposition between the cellular capsule and the elements destined to become the zona glomerulosa. A subtle hint of arcades can be detected near capsule. A large sinus separates cortex and medulla in this section. Stained with Mallory's triple. Magnification X 410.

Fig. 4. Outer cortical area photograph of adrenal gland from an 8-hour old female (B9). Higher magnification of Fig. 3, showing capsule and cortical relationships. Note highly cellular capsule and centrally located trabeculae which penetrates into the cortex. Zona glomerulosa cells adopting a different organizational relationship. Stained with Mallory's triple. Magnification X 1020.

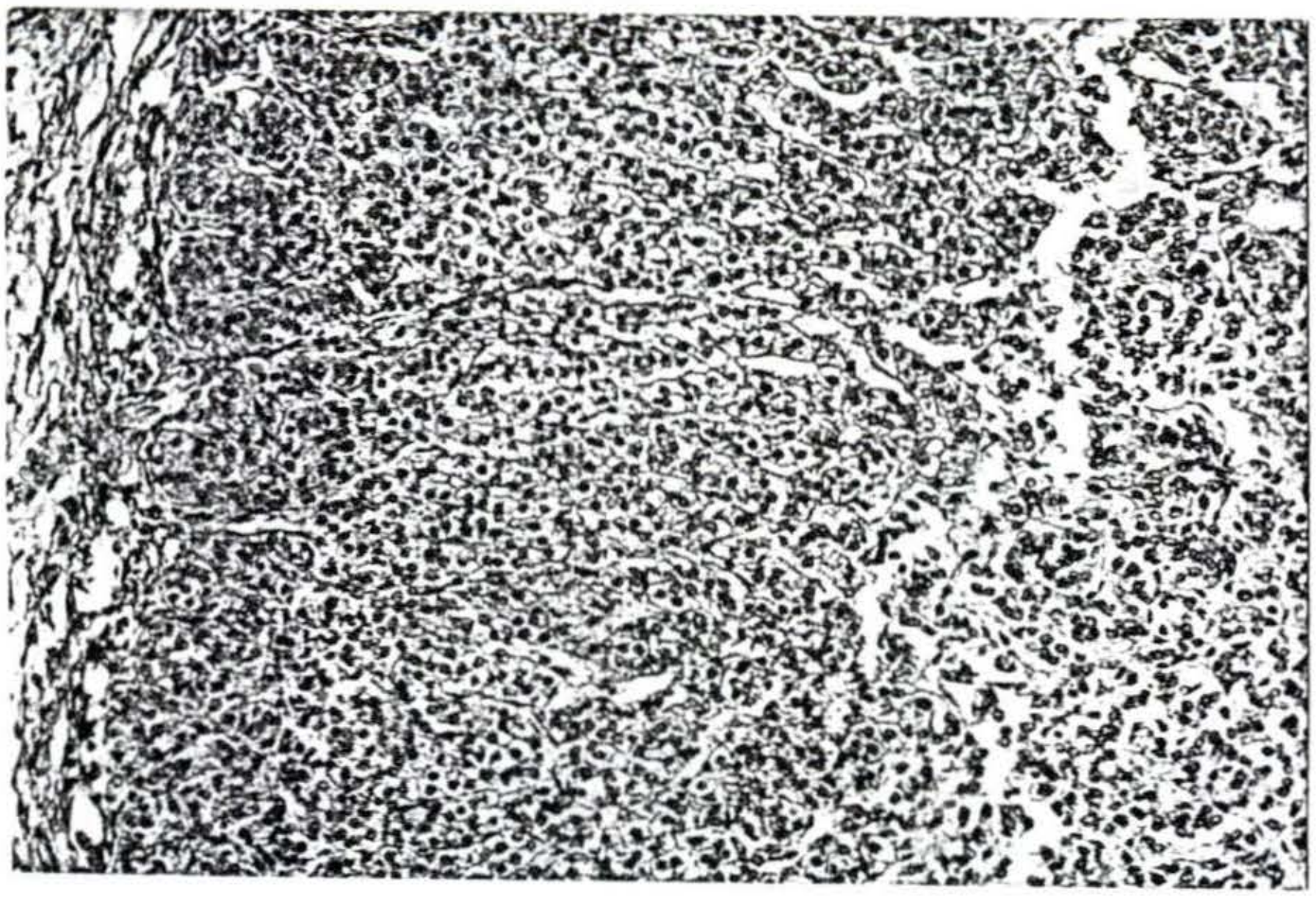

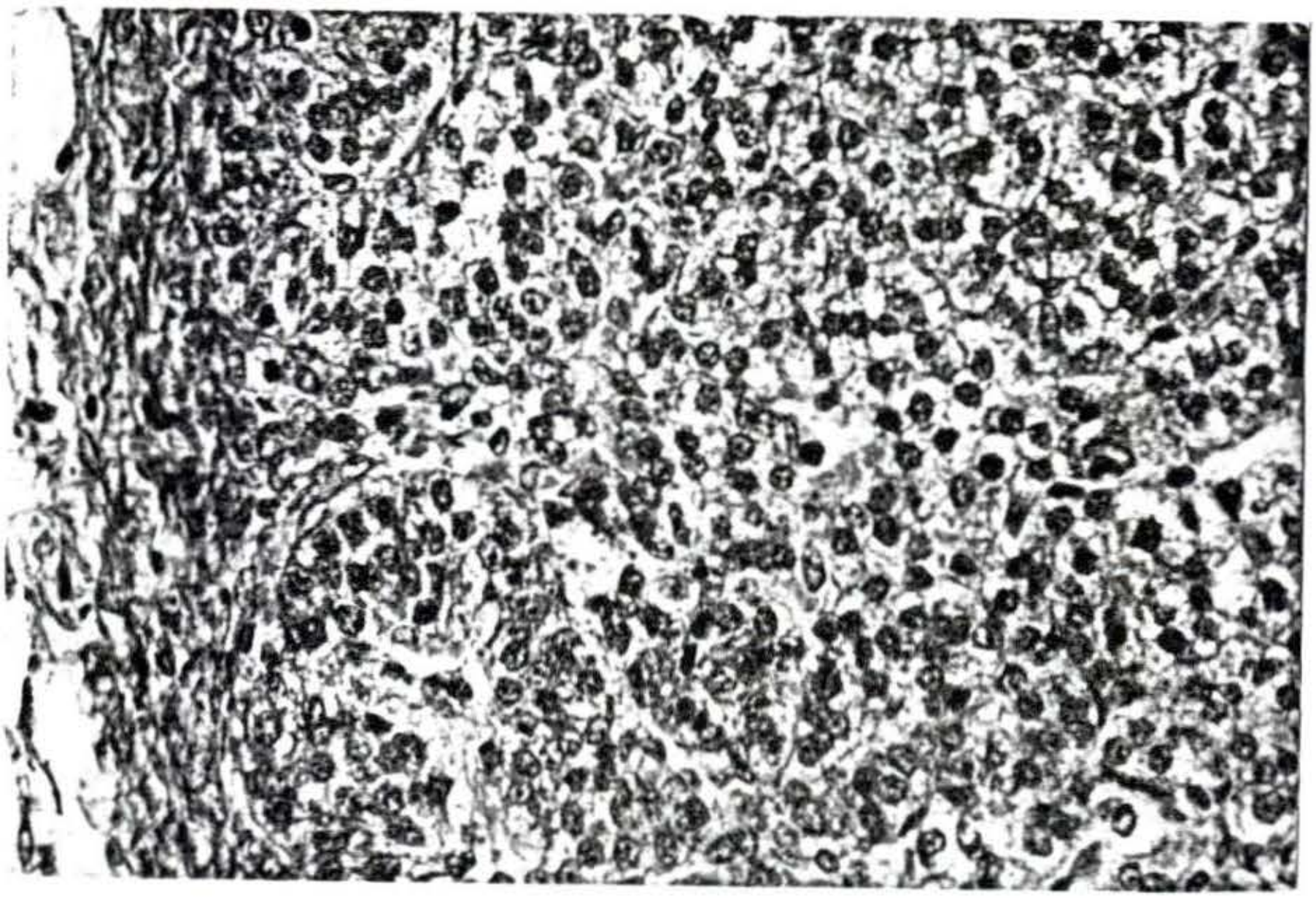

Fig. 5. Periadrenal fatty tissue of adrenal gland from 8-hour old female canine (B9). Portions of three nodules of fatty connective tissue are shown in photograph. Note signet ring cells already present among spongiocyte-like cells. These nodules were seen up to 1 year. Stained with Mallory's triple. Magnification X 1020.

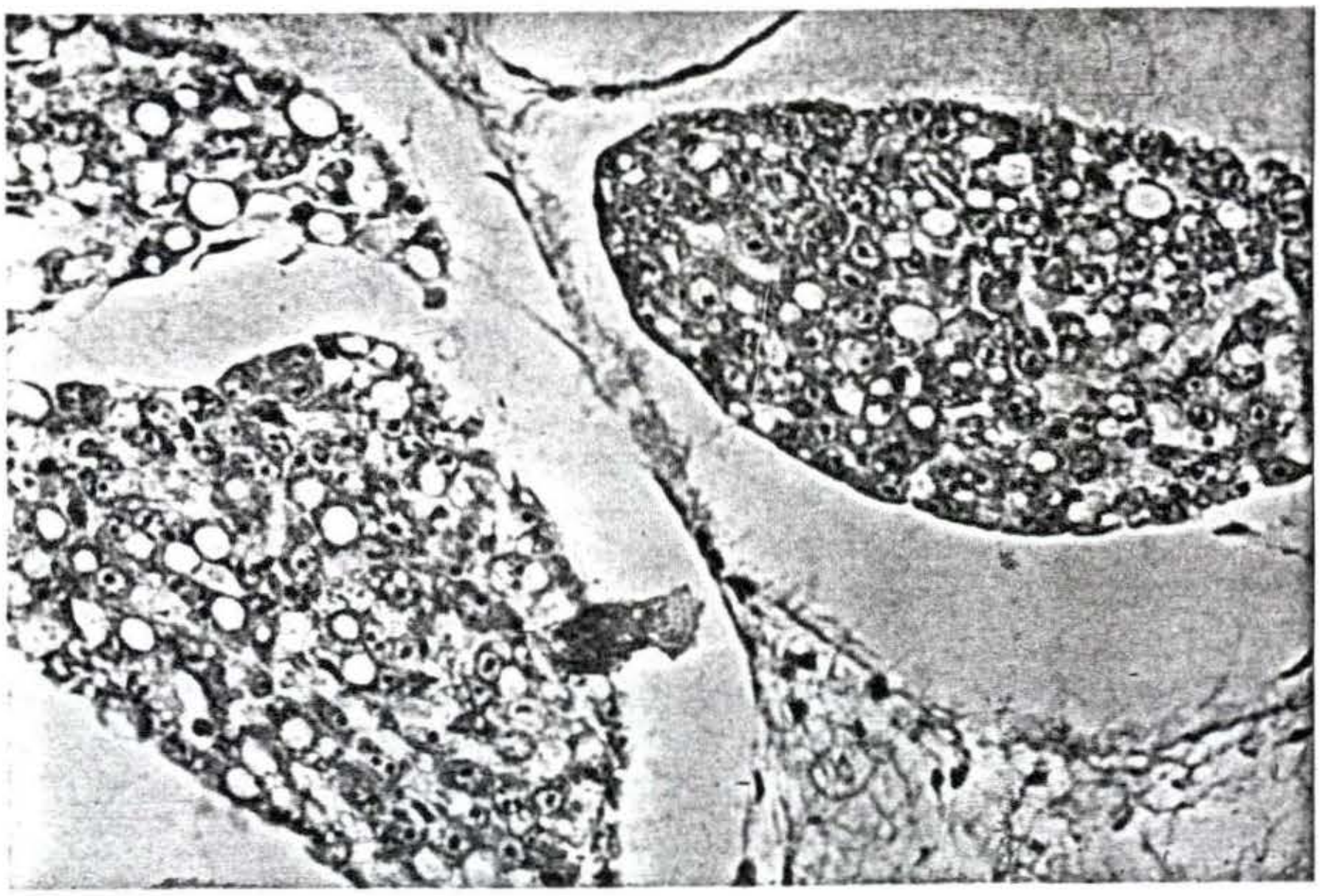

Fig. 6. Cross section of an adrenal gland from a 100-day old male canine (B27). The large capsular trabeculae (CT) is extended to the cortico-medullary border. The glomerulosa (G), fasciculata (F) and reticularis (R) are well differentiated cortical zones. The medulla (M) contains large medullary vein (mv). Stained with Mallory's triple. Magnification X 28.

Fig. 7. Cross section of adrenal gland from a 206-day old female canine (B61). Showing well developed glomerulosa (G) and fasciculata (F). The reticularis (R) is not well developed. Capsular artery (CA) very prominent. Medulla (M). Stained with Mallory's triple. Magnification X 25.

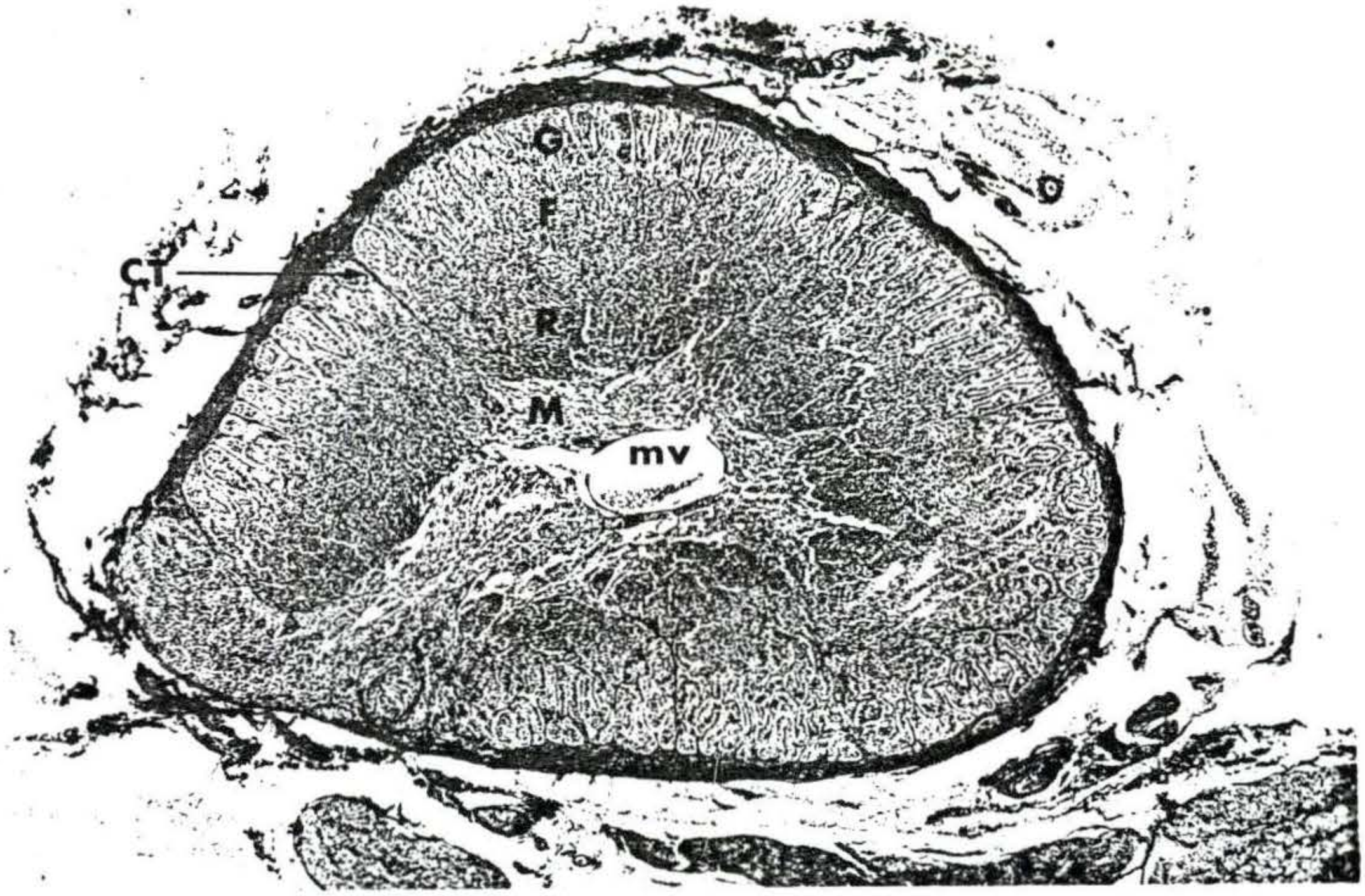
G
F
CT
R
M
mv

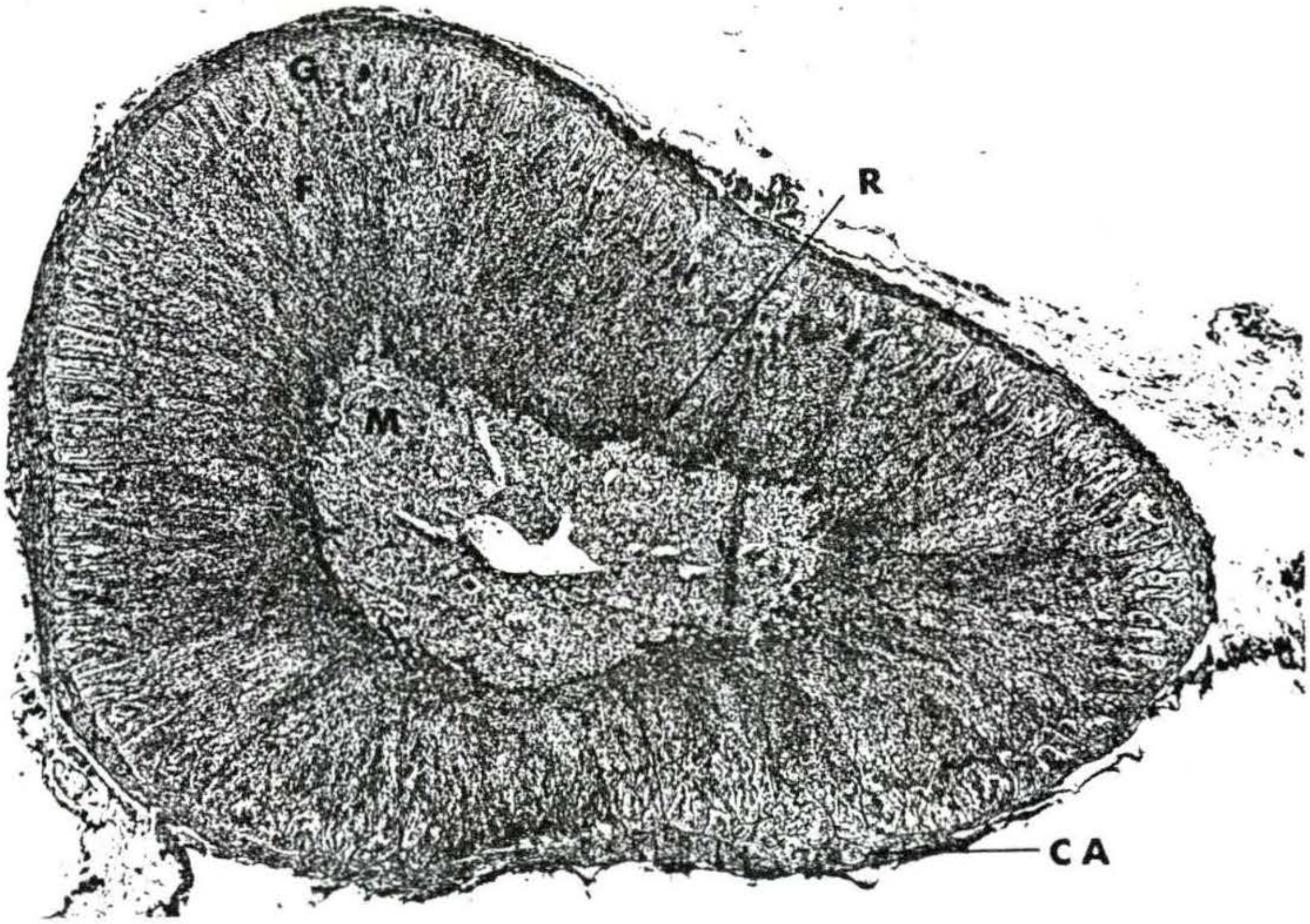
G
F
R
M
CA

Fig. 8. Overall view of cortex of adrenal gland from a 100-day old male canine (B27). Note the arcade formation and the continuation of glomerular cell columns with the zona fasciculata parenchyma. Capillary sinuses separate the fascicular cords in some areas. Stained with Mallory's triple. Magnification X 410.

Fig. 9. Cross section of adrenal gland from a 1-year old female canine (B62). Note the well differentiated zona glomerulosa (G) zona fasciculata (F) and zona reticularis (R). The zona intermedia (Z) is outlined by the arrow and pointer. The black arrows point to numerous intracapsular cortical cell nodules some of which are connected with the underlying zona glomerulosa. Stained with Mallory's triple. Magnification X 20.

Fig. 10. Cross section of adrenal gland from a 1.9-year old female canine (B13). Prominent trabeculae (CT) course between the arcades and pass into the boarder of the zona fasciculata (F) and zona glomerulosa. A zona intermedia can be seen. Reticularis (R). Black arrow indicates intracapsular cortical cell nodule. Stained with Mallory's triple. Magnification X 21.

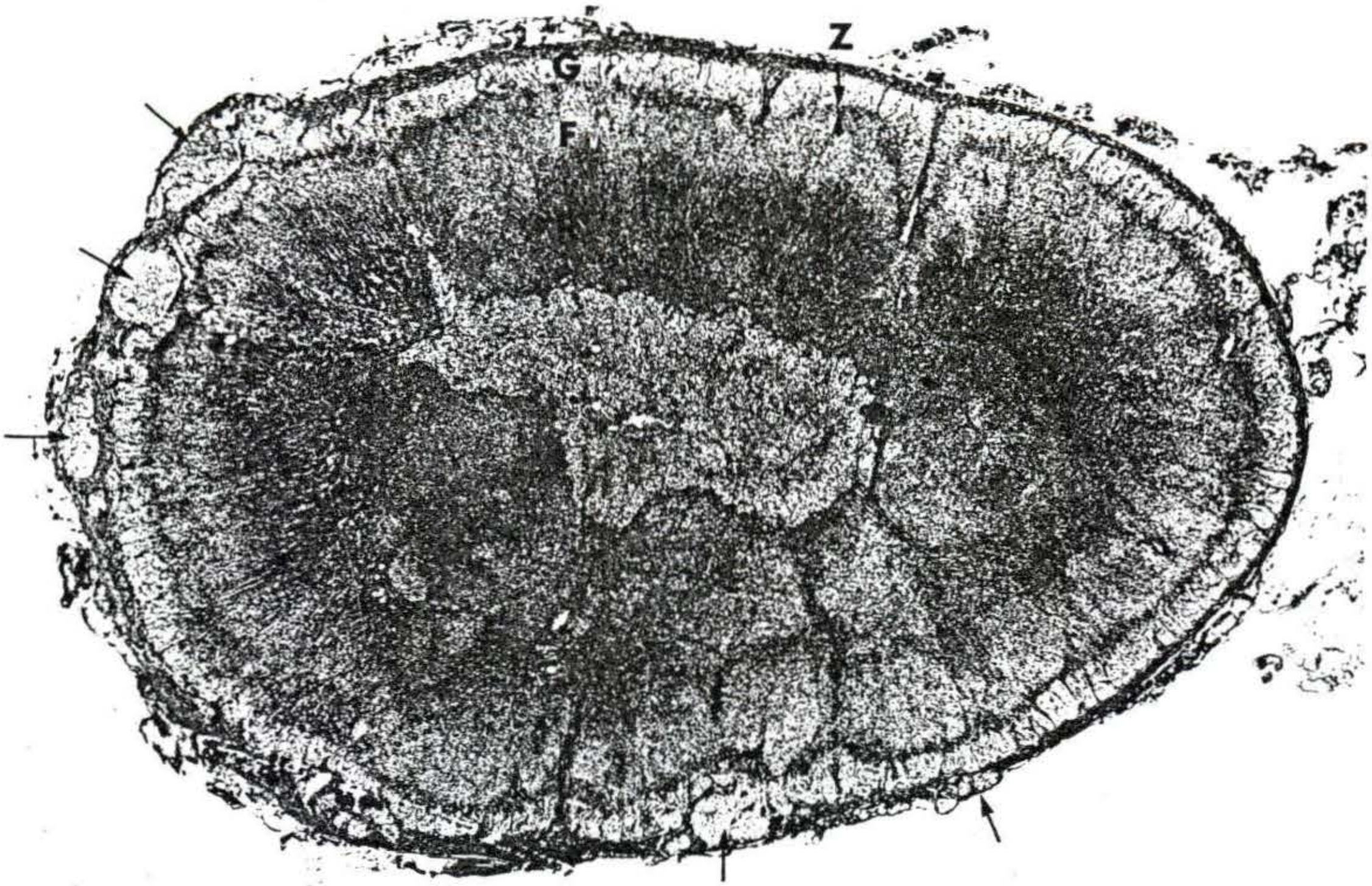
Z
G
F

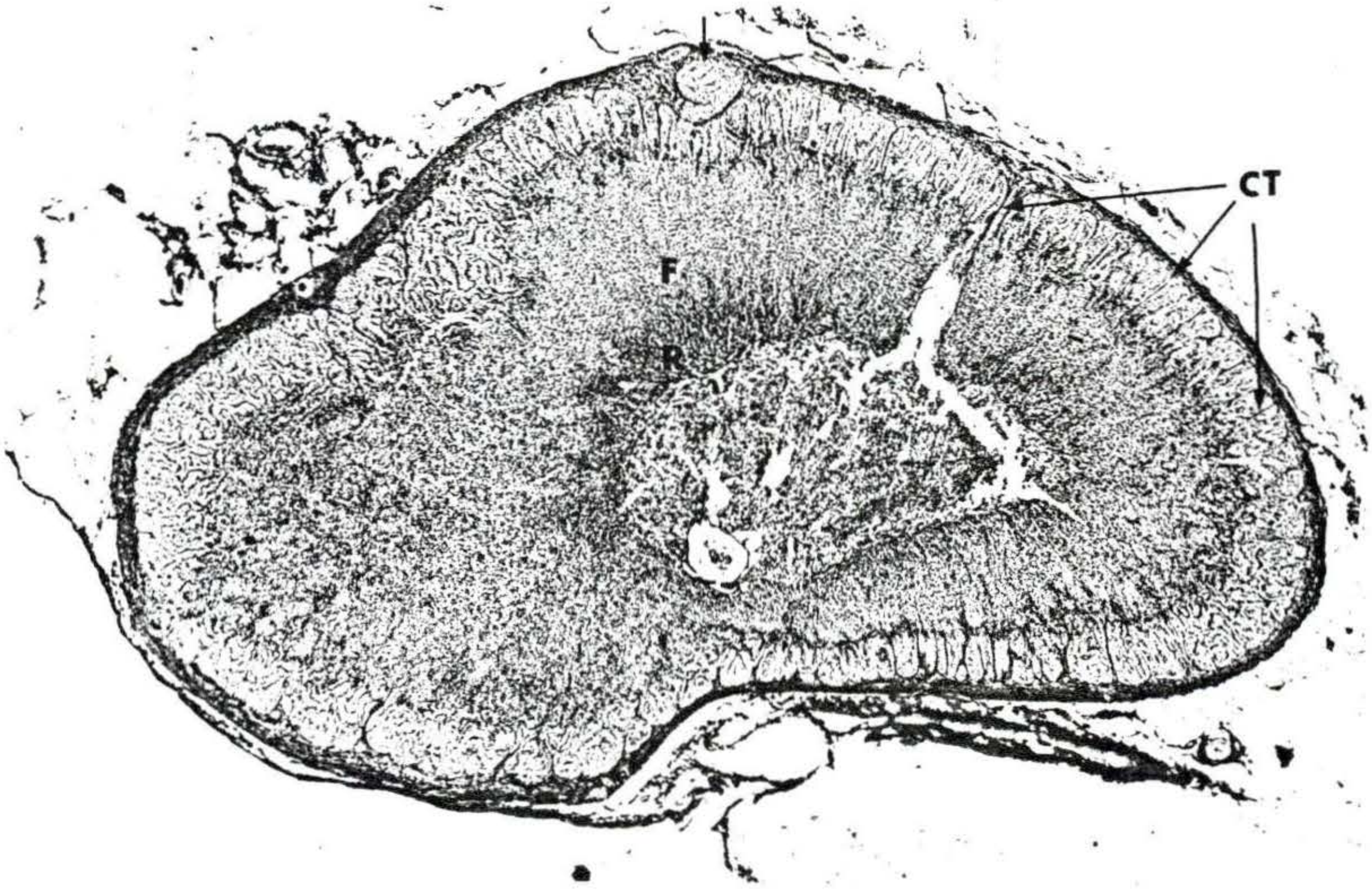
CT
F
R

Fig. 11. Overall view of the cortex of 1-year old female canine (B62). The zona intermedia can be seen at the junction of glomerulosa and fasciculata. Note the dark staining cells of the reticularis and the collagenous fibers at the cortico-medullary boarder as well as those fibers pervading the medulla. An intracapsular nodule can just be seen at the uppermost part of the photograph. Stained with Mallory's triple. Magnification X 165.

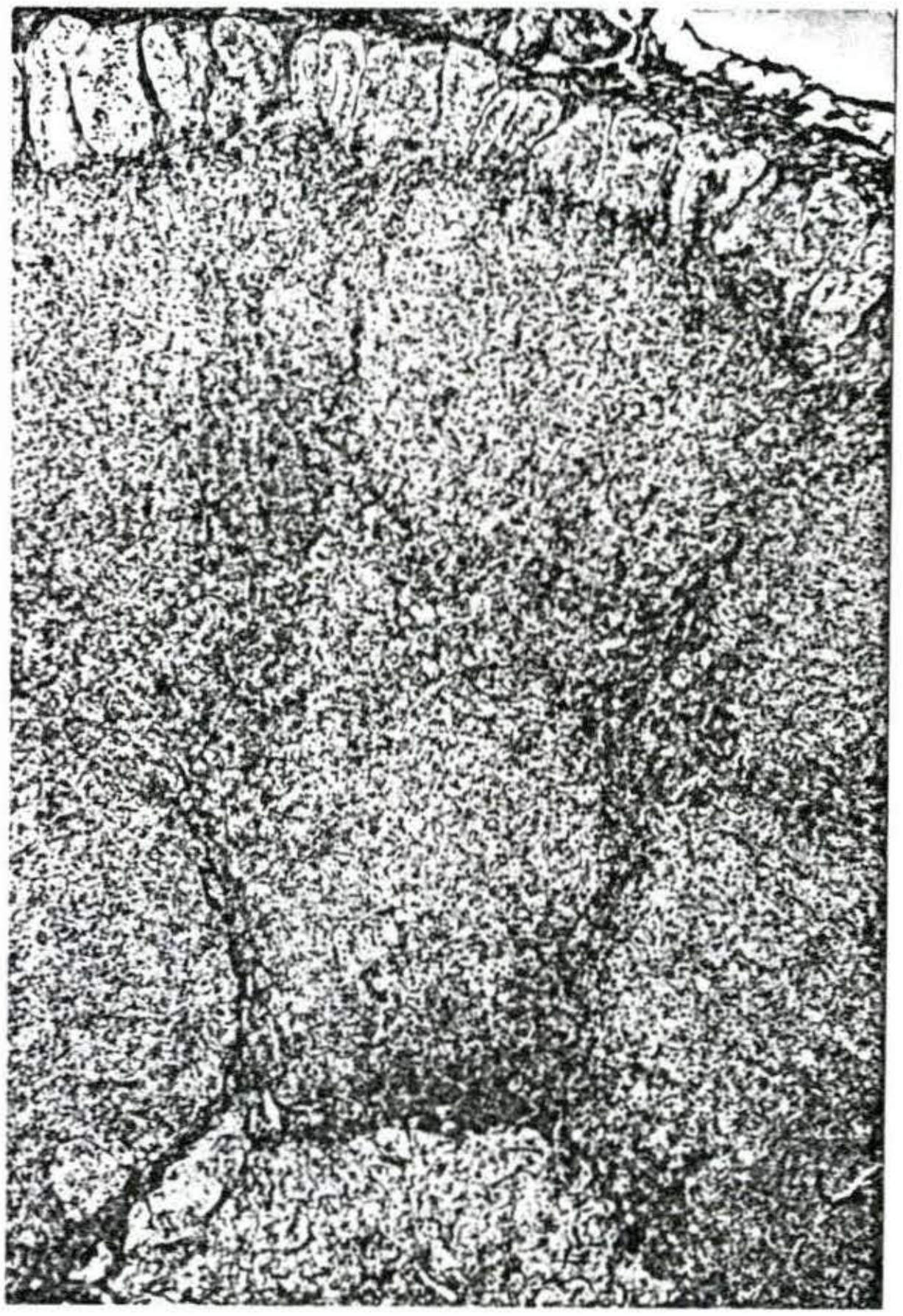

Fig. 12. Cross section of adrenal gland from a 3.4-year old male canine (B20). Section taken from near the hilus of the gland, note where the cortex narrows and the medulla appears to approach the surface. Nervous tissue (N) fasciculata (F), reticularis (R), and medulla (M) with numerous medullary sinuses. Note that sinus spaces now appear in the zona reticularis. Stained with Mallory's triple. Magnification X 23.

Fig. 13. Cross section of adrenal gland from a 3.6-year old female canine (B65). Note the prominent trabeculae passing into the cortex. Black arrows indicate intracapsular nodules of cortical cells and in one area an, apparently, evaginating nodule has a broad base in the zona glomerulosa. Fasciculata (F), medulla (M) and reticularis (R) within which white arrows point to "punched out" areas which have undergone fatty metaplasia. Stained with Mallory's triple. Magnification X 20.

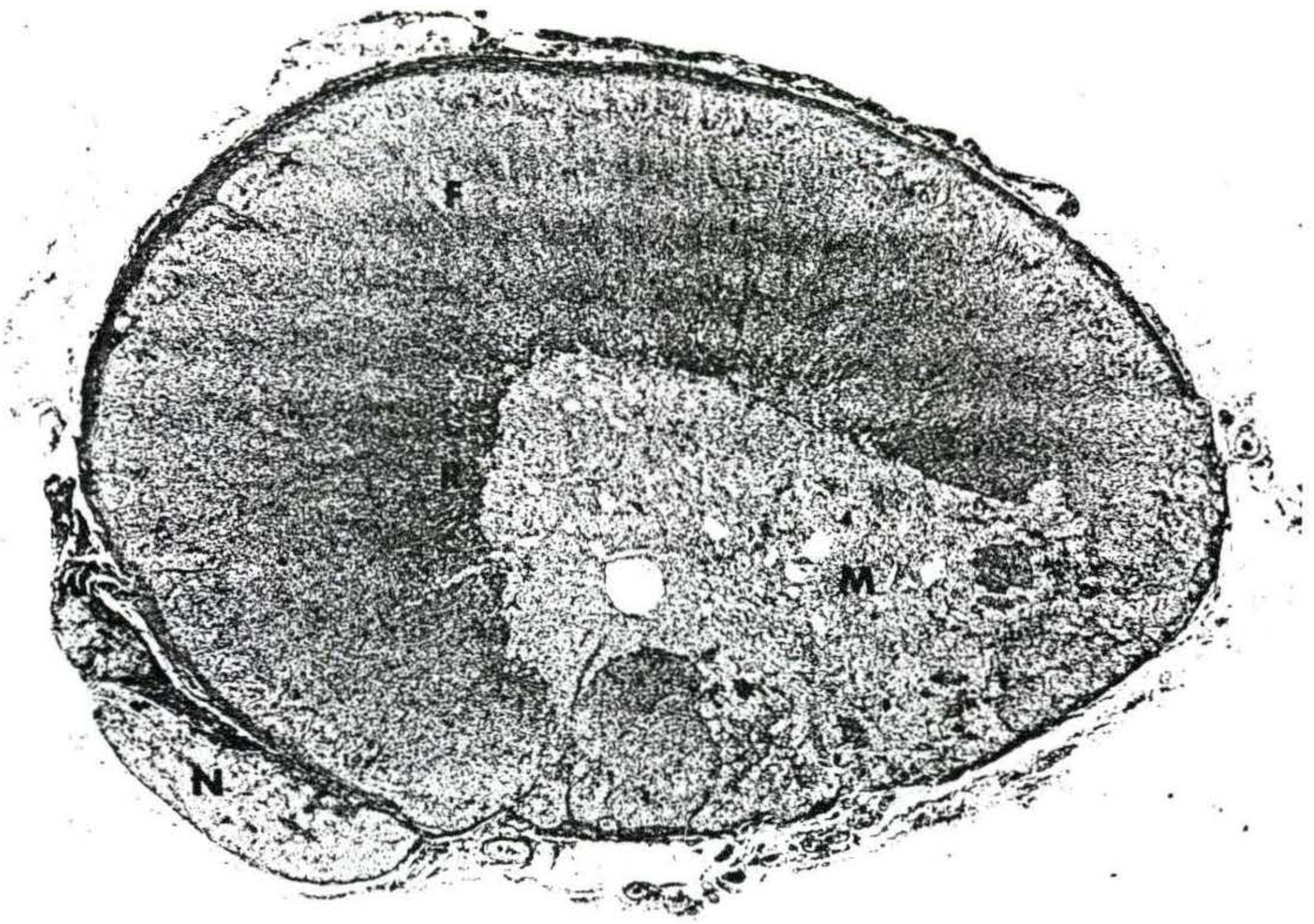
F
R
M
N


F
M

Fig. 14. Overall cortical view of adrenal gland from 3.6-year old female canine (B65). An intracapsular nodule is present. A large and very prominent zona reticularis, occupied 37% of the cortical volume according to the quantitative procedures, and, in the area included in this photograph, even a larger percentage. Note the well rounded areas which on higher magnification were noted to be surrounded by parenchymal cells of normal appearance. The collagenous elements at the periphery of the medulla are increased in amount. Stained with Mallory's triple. Magnification X 165.



Fig. 15. Cross section of adrenal gland from a 4.2-year old female canine (B51). There is a very uniform zona glomerulosa which is limited by a zona intermedia (Z) and in the lower portion of the photograph can be seen to have evaginated through the capsule. Fasciculata (F), reticularis (R). A white arrow indicates areas of degenerative change. Stained with Mallory's triple. Magnification X 17.

Fig. 16. Cross section of adrenal gland from a 6-year old female canine (B18). The morphological relationships of the zona glomerulosa (G), zona fasciculata (F) and zona reticularis (R) are especially well defined. Although not labeled, one can distinguish a division in the zona fasciculata (F) into inner and outer regions. Supracapsular nodule extended from the glomerulosa (black arrow). Degenerative changes within the zona reticularis (white arrow). Stained with Mallory's triple. Magnification X 16.

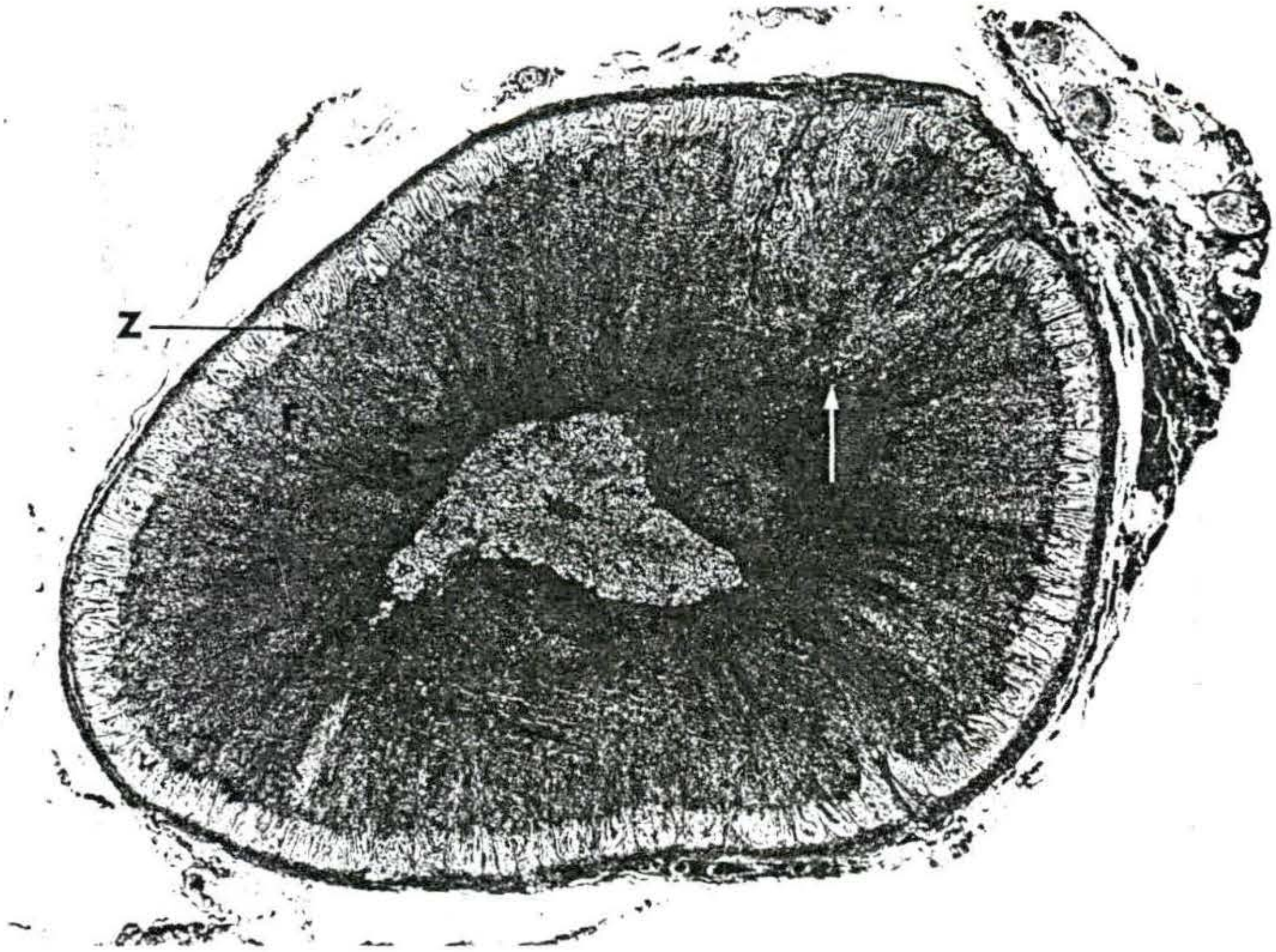
Z
F

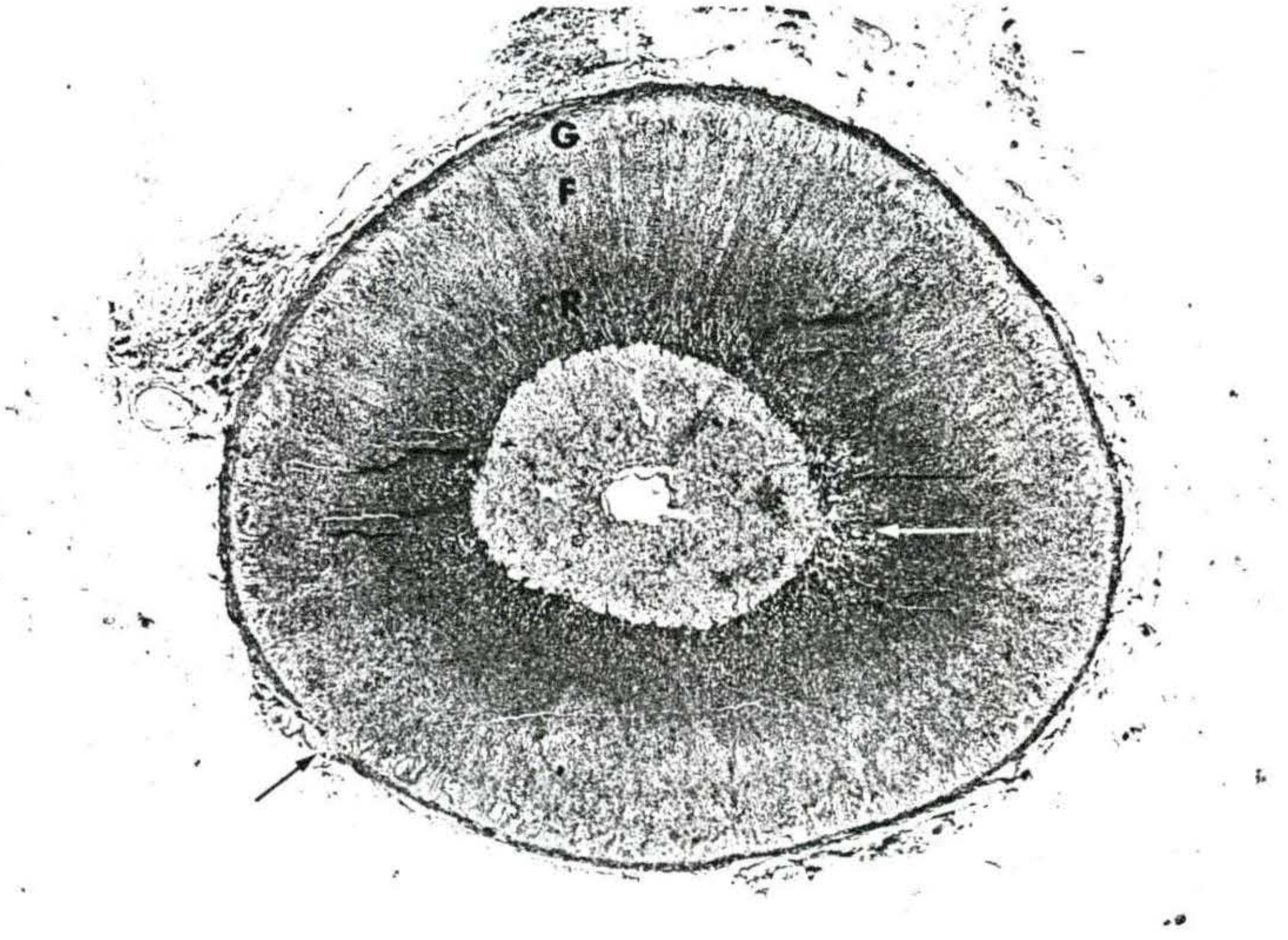
G
F
R

Fig. 17. Longitudinal section of adrenal gland from a 7.5-year old female canine (B30). Note the hilus region (H) containing large vascular elements. Observe that the gland is divisible grossly into an anterior and posterior portion. The zona fasciculata (F) in this section bridges across the medulla (M). Note the medullary vein (mv). Black arrows indicate supracapsular nodules where communication with the underlying zona glomerulosa can be seen. Trabeculae which are lined with glomerular elements are seen (CT) on longitudinal and cross section. A well defined zona intermedia (Z). Stained with Mallory's triple. Magnification X 7.

Fig. 18. Cross section of adrenal gland from a 9.1-year old male canine (B63). (Z) indicates a well-defined zona intermedia. Reticularis shows areas of degenerative change and fatty metaplasia (white arrows). Capsular and pericapsular cortical cell nodules (black arrows). Stained with Mallory's triple. Magnification X 15.

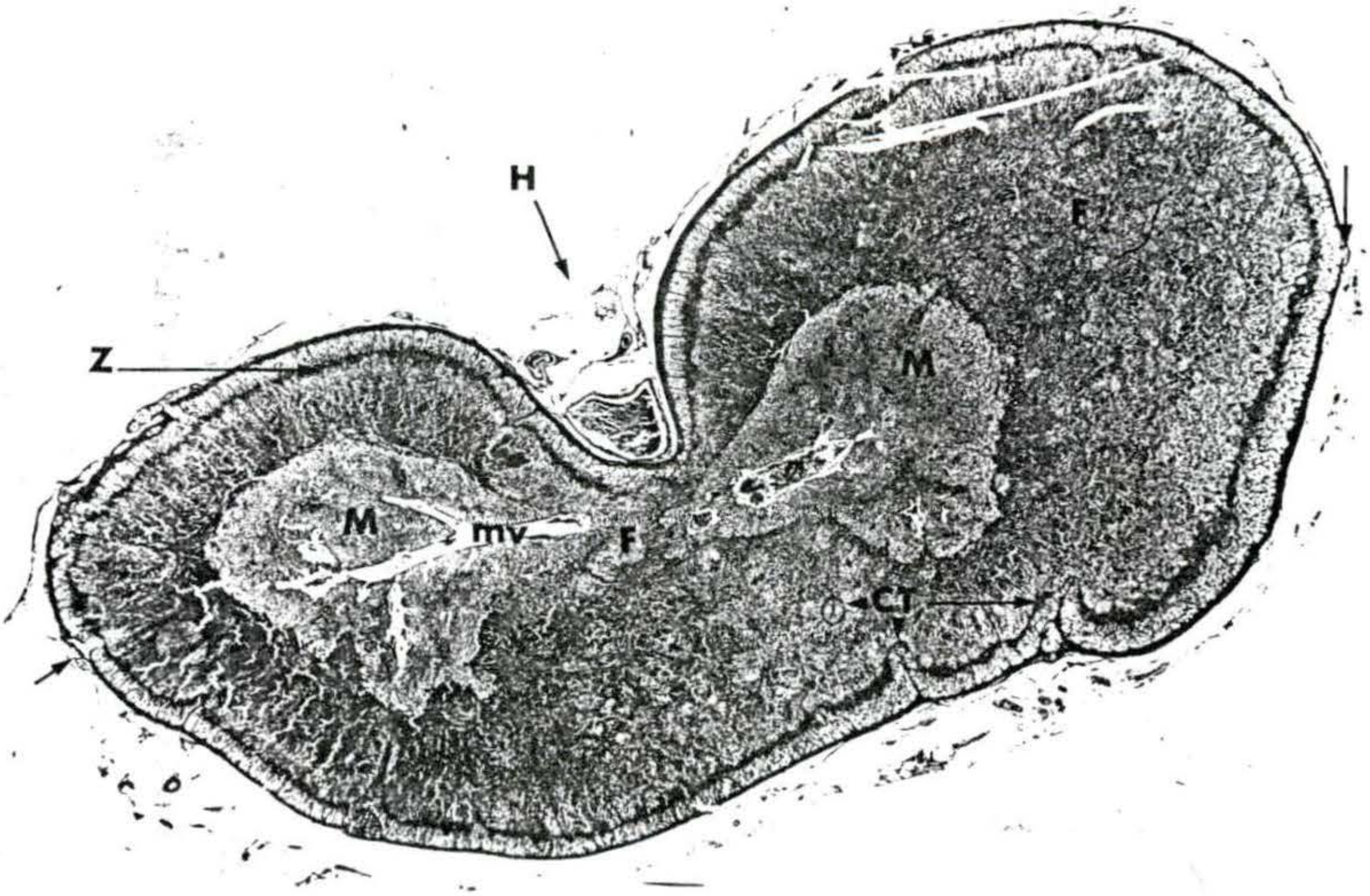
H
Z
M
mv
F
M
F
Ct

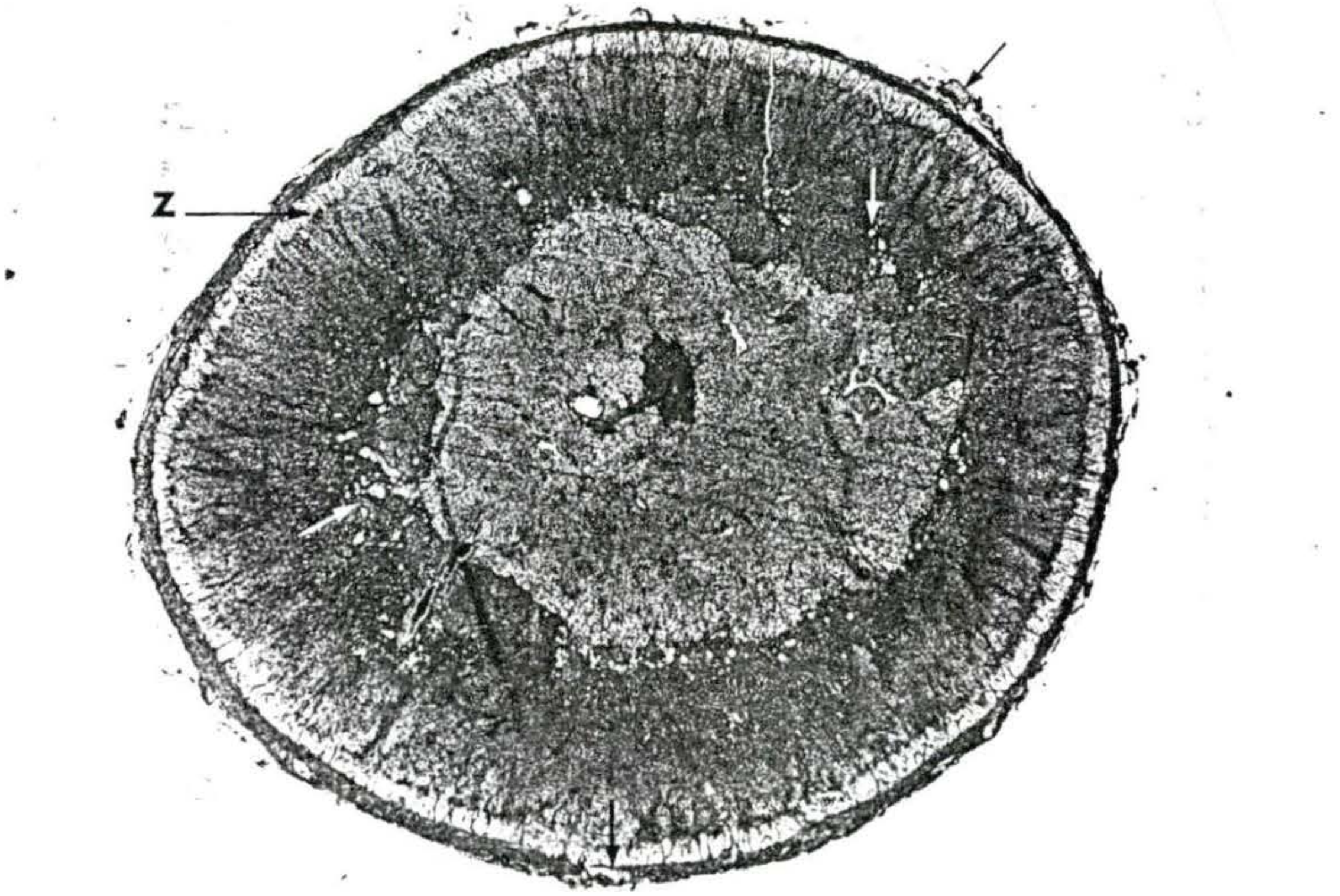
Z

Fig. 19. Overall cortical view of adrenal gland from a 7.5-year old female canine (B30). Note the nodule formation and apparent evagination of glomerular cells. Darker staining cells of zona intermedia are present. Stained with Mallory's triple. Magnifications X 165.

Fig. 20. Overall cortical view of adrenal gland from a 9.1-year old male canine (B63). Observe the fatty metaplasia and degenerative changes occurring in cells of the zona reticularis. Stained with Mallory's triple. Magnification X 165.

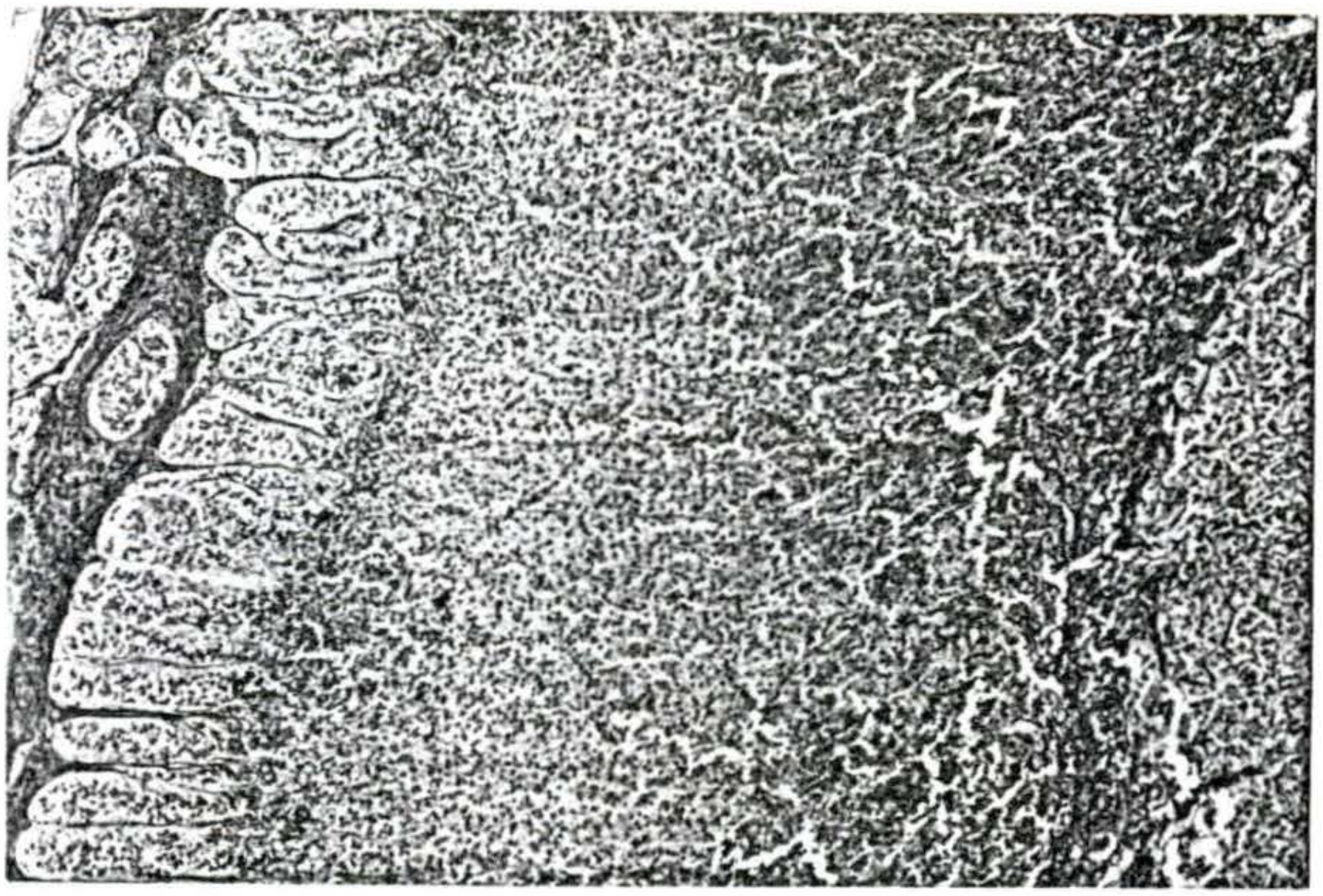

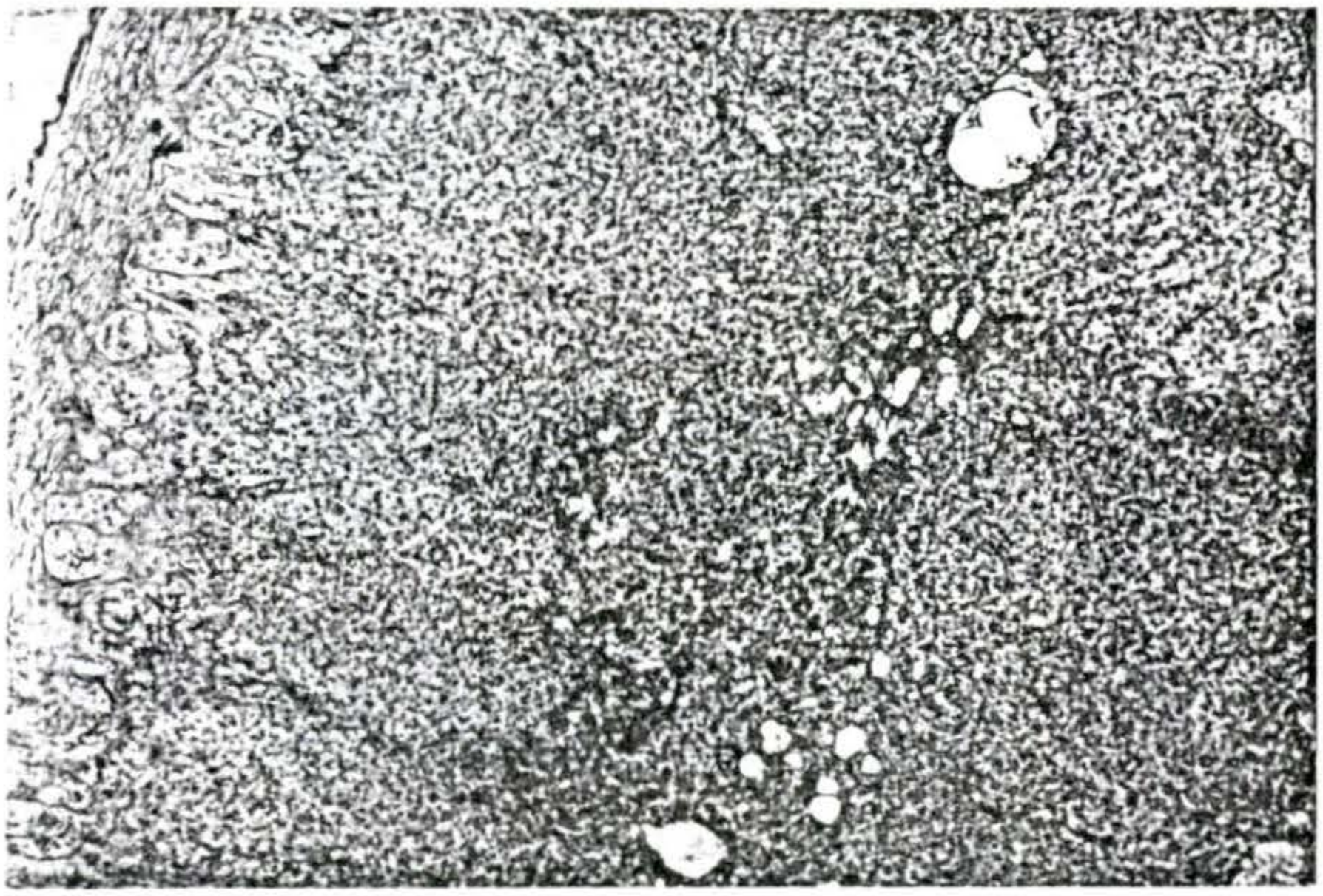

Fig. 21. Cortical zones of adrenal gland from 9.1-year old male canine (B63).

A. Zona glomerulosa. Note characteristic columnar cells have been out in many differing planes of section. The capsule can be seen in upper left of photograph (white arrow). The cells are bounded by fine fibers of connective tissue, through which, course capillaries. Stained with Mallory's triple. Magnification X 1100.

B. Zona glomerulosa. Columnar cells of arcades can be seen in many differing planes of section. Capsule (black arrow) is the outer boundary for the zone. The cells are highly vacuolated and contain vascicular nuclei which are centrally located within the cell. Stained with Mallory's triple. Magnification X 1100.

C. Zona fasciculata. Note the highly vacuolated cells arranged in cords between which pass capillary sinuses. Stained with Mallory's triple. Magnification X 1100.

D. Zona fasciculata. Cross sectional view of fascicular cords. The cells are smaller than glomerular cells and are polyhedral in shape and contain a dense staining nucleus. Stained with Mallory's triple. Magnification X 1100.

E. Zona reticularis. Note the cells appear smaller and some contain pyknotic nuclei. Black arrow points to cells having undergone fatty metaplasia. Stained with Mallory's triple. Magnification X 1100.

F. Zona reticularis. Note small cells with pyknotic nuclei and extensive fatty metaplasia (Black arrow). Stained with Mallory's triple. Magnification X 1100.

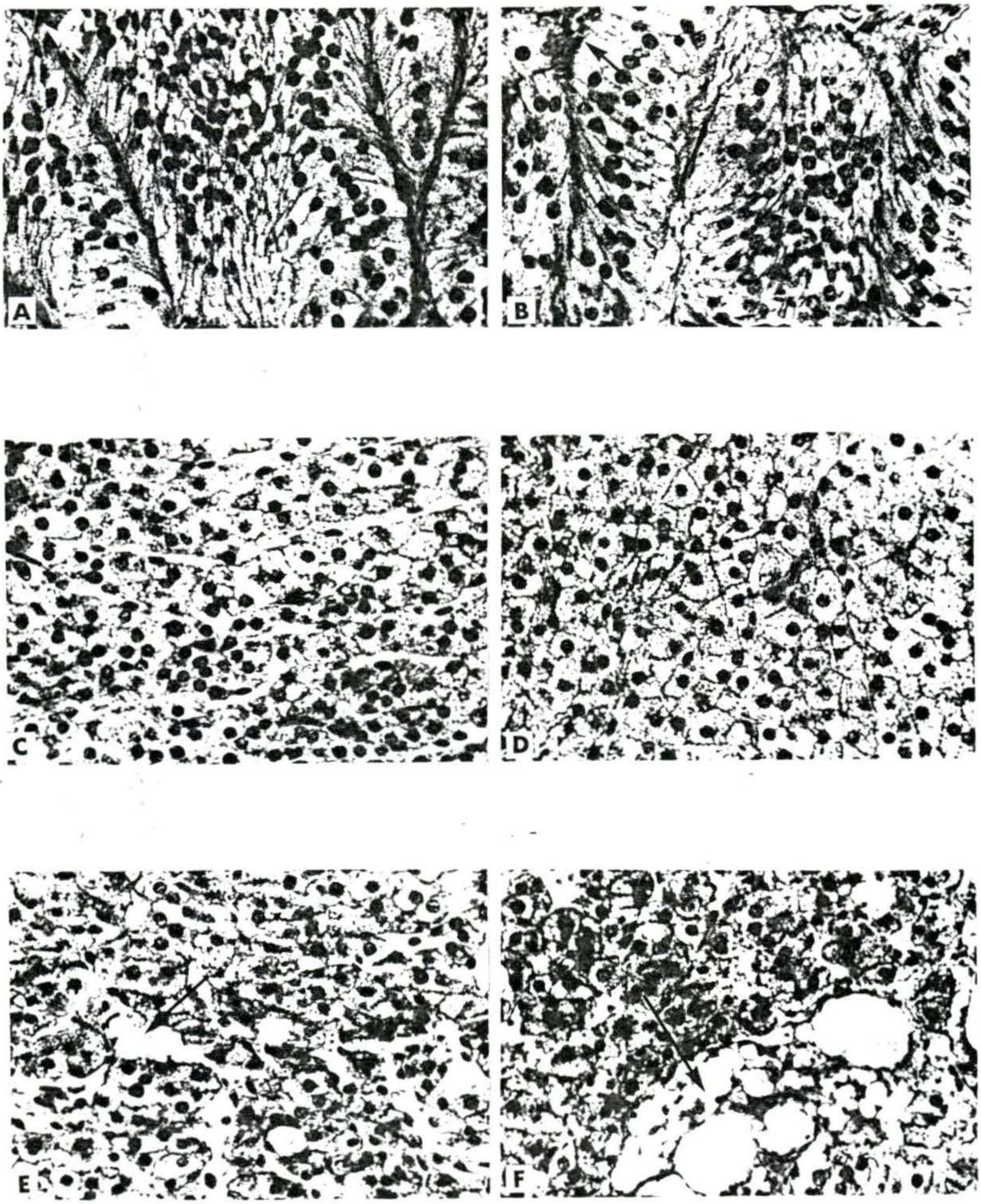
A
B
C
D
E
F

Fig. 22. Cross section of adrenal gland from a 10.4-year old female canine (B15). Observe the large evaginated cortical cell nodules (black arrows). White arrows indicate areas of fatty degeneration in reticularis. Medulla (M) divided in this section by fasciculata (F). Well developed zona intermedia. Stained with Mallory's triple. Magnification X 15.

Fig. 23. Cross section of adrenal gland from a 12.9-year old female canine (B17). Numerous pericapsular cortical cell nodules also showing connections with the glomerulosa (black arrows). Fasciculata (F) and reticularis (R) showing degenerative changes (white arrows). Stained with Mallory's triple. Magnification X 14.

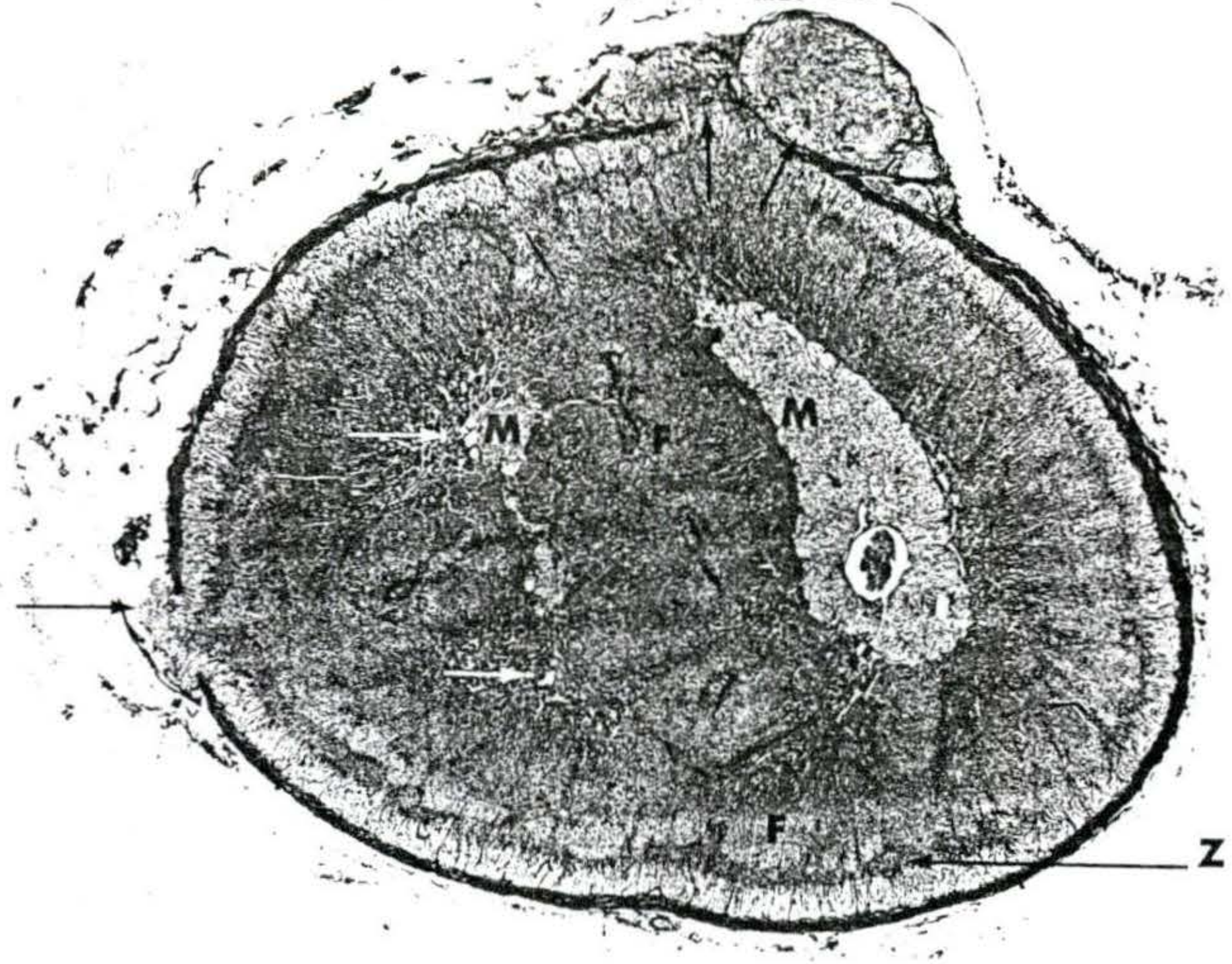
M
F
M
F
Z

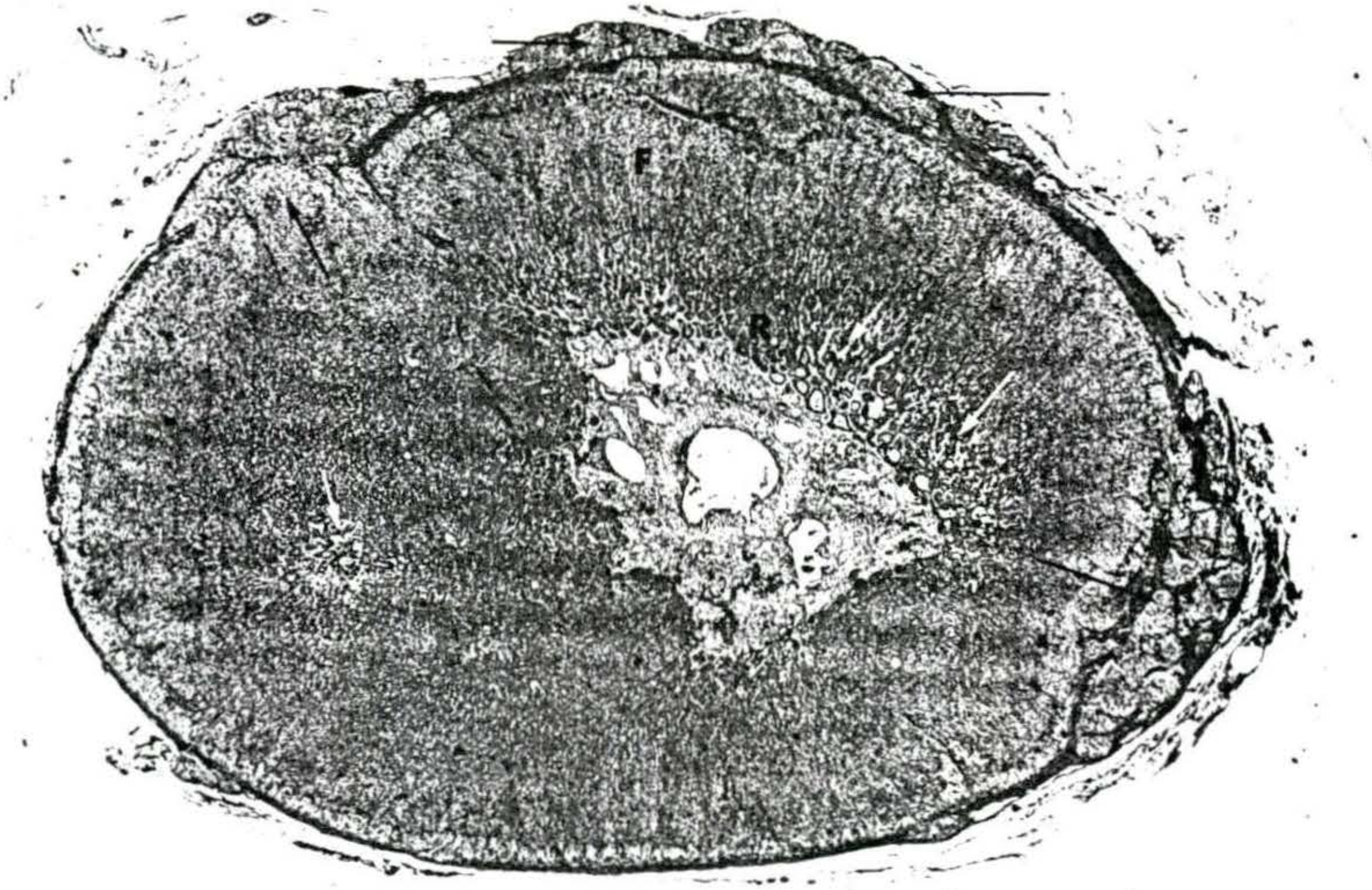
F
R

Fig. 24. Tangential section of adrenal gland from a 13.6-year old female canine (B14). Note the fasciculata (F) due to tangential sectioning appears also where medulla normally seen. The reticularis is very extensive and white arrows indicate the areas of fatty metaplasia. The glomerulosa (G) is in many areas connected to pericapsular nodules of cortical cells (black arrows). (A more detailed study of the nodule in the lower right of the photograph will follow. See Figs. 26 and 27.) Stained with Mallory's triple. Magnification X 16.


G
F

Fig. 25. Overall cortical view of adrenal from 13.6-year old female canine (B14). Note the communication of cortical cell nodules with the glomerulosa by way of a "stock" through the capsule. Tangential sectioning reveals much zona reticularis parenchyma. Stained with Mallory's triple. Magnification X 165.

Fig. 26. Pericapsular cortical cell nodule from adrenal gland of 13.6-year old female canine (B14). Refer to Fig. 24. Note the general size and amount of capsular surface covered by this "mushrooming" nodule and the connection by a "stock" through the capsule to the underlying zona glomerulosa. Stained with Mallory's triple. Magnification X 412.

Fig. 27. Higher magnification of pericapsular nodule stock shown in Fig. 26. (13.6-year old, B14). Note opening in capsule. The origin of the dark staining cells of the "stock" of this nodule is questionable. Perhaps, they are zona intermedia cells. Stained with Mallory's triple. Magnification X 1020.

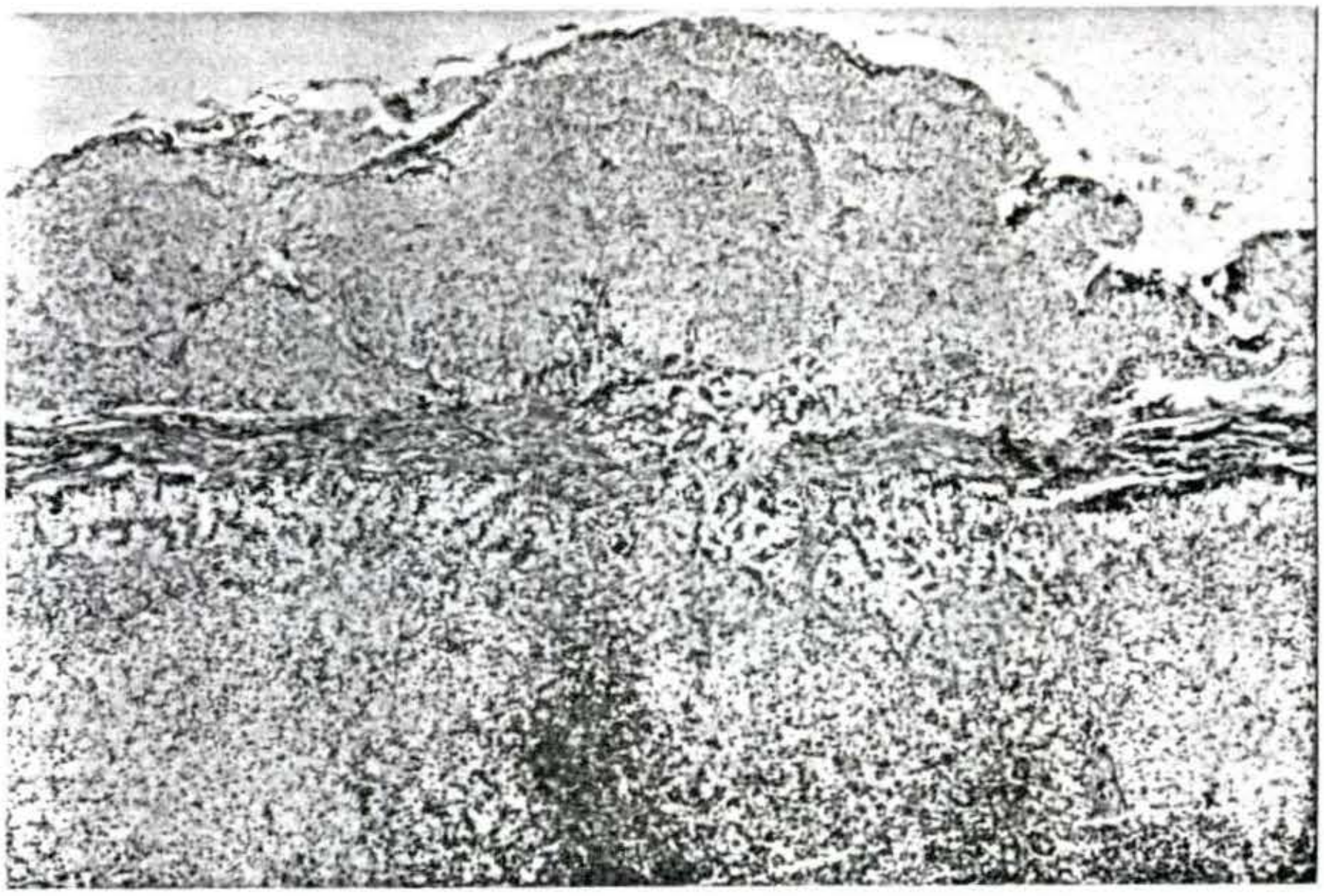

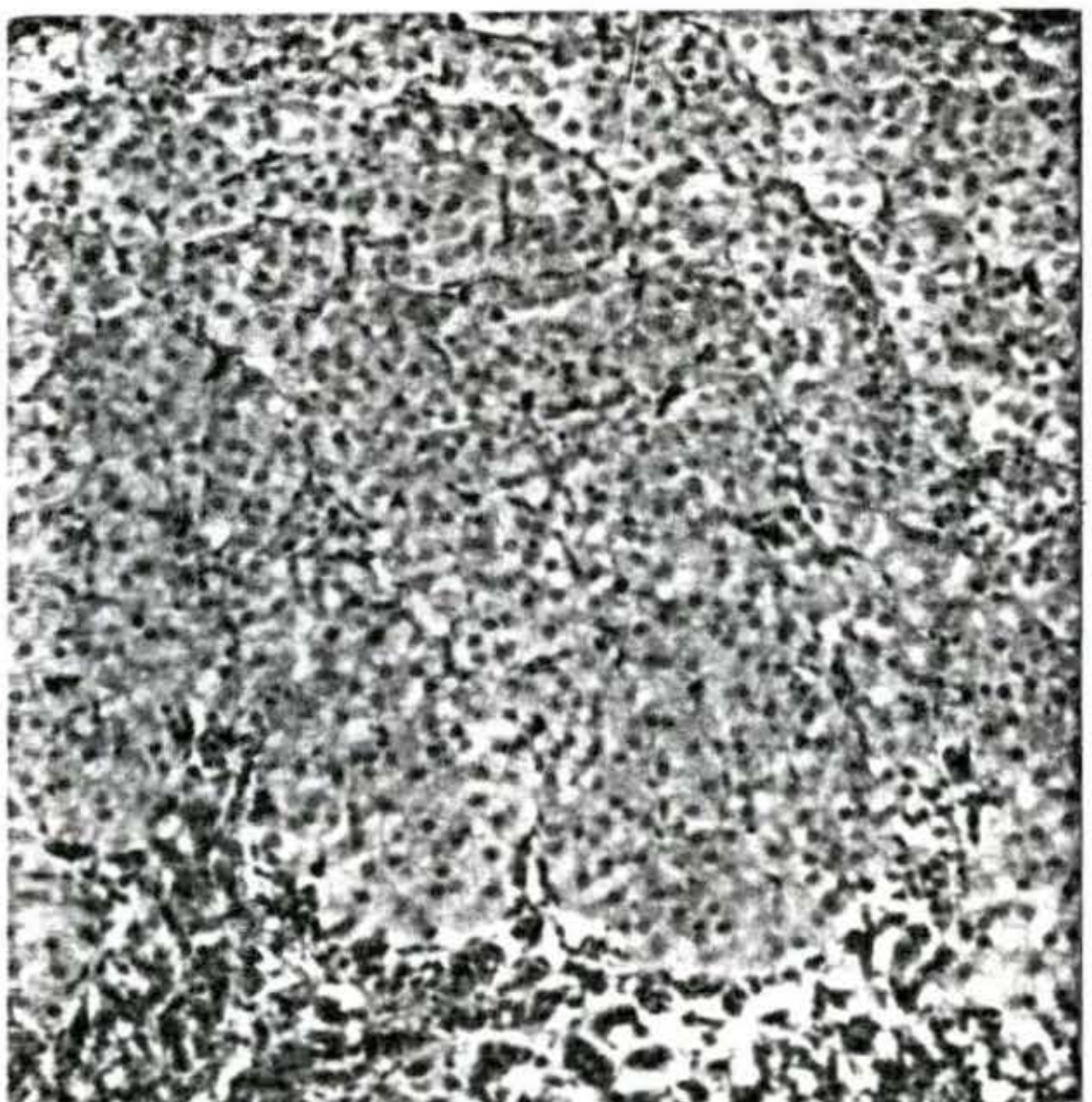

Fig. 28. Overall cross section of cortex of adrenal from 9.1-year old male canine (B63). Schultz cholesterol reaction. (Blue-green is positive test.) Note that intracapsular nodule is continuous with glomerular cells and that all of cells in this area are positive for cholesterol storage. (Dark circles are procedural artifacts introduced by the final complex-forming reaction.) Schultz cholesterol reaction. Magnification X 165.

Fig. 29. Overall view of cortex of adrenal from 7.8-year old female canine (B44). Note positive cholesterol reaction in cortex except for the zona intermedia. The capsule and medulla are negative. (Dark circles are procedural artifacts introduced by the final complex-forming reaction.) Schultz cholesterol reaction. Magnification X 165.

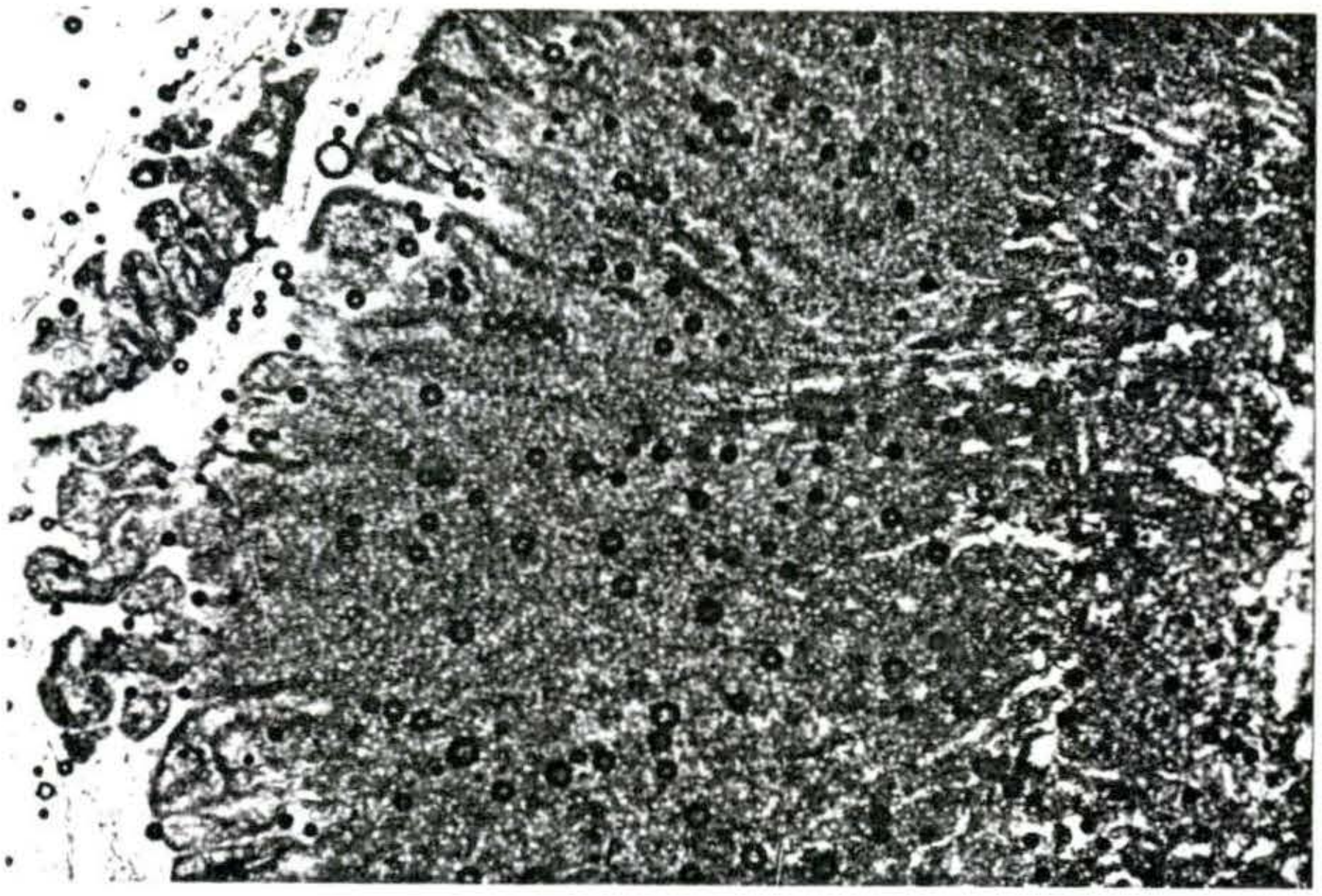



Fig. 30. Intracapsular nodule of an adrenal from a 9.1-year old male canine (B63). Note the apparent distinct demarcation between nodule and capsular elements. The columnar zona glomerulosa cells with centrally located nucleus are easily detected. Stained with oil red O and counter stained with Groats hematoxylin. Magnification X 1020.

Fig. 31. Evaginated glomerular cell elements of an adrenal from a 6.0-year old female canine (B18). Note the complete opening in capsule, the continuation of the main evaginated mass with a glomerular arcade and another glomerular arcade partially through the capsule. Stained with Heidenhain-Van Giesen-Weigert. Magnification X 410.

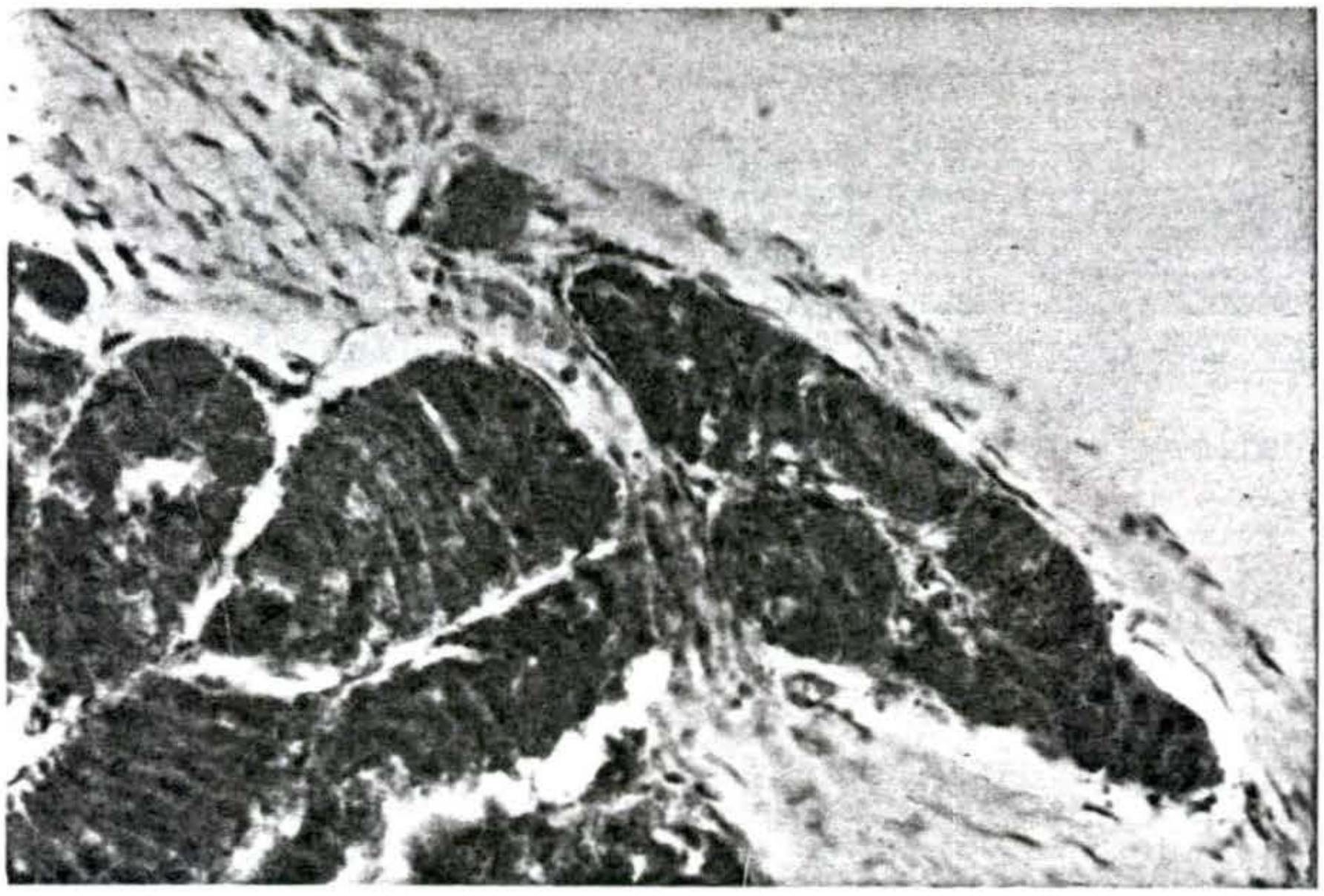

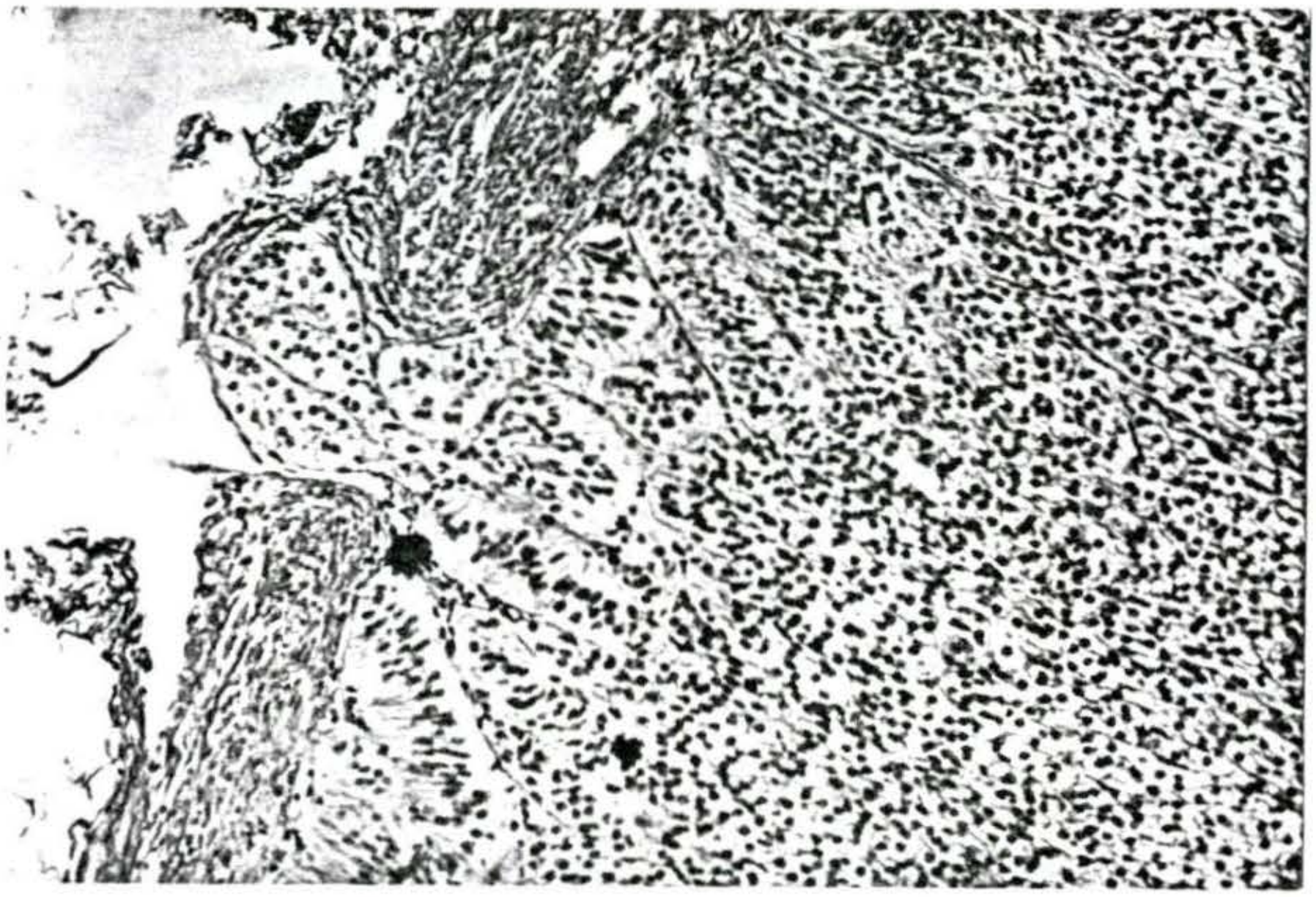

Fig. 32. Cortico-medullary border of adrenal from 1.9-year old female canine (B11). On the left portion of the photograph note the aggregates of normal reticularis cells separated by endothelial-lined capillary sinuses. The right one-fifth of the photograph is the medulla. Diffuse blue staining collagenous fibers separate the two areas. Stained with Mallory's triple. Magnification X 1650.

Fig. 33. Reticularis of adrenal from 12.9-year old female canine (B17). Note the diffuse areas of fatty metaplasia and degeneration. Stained with Mallory's triple. Magnification X 412.

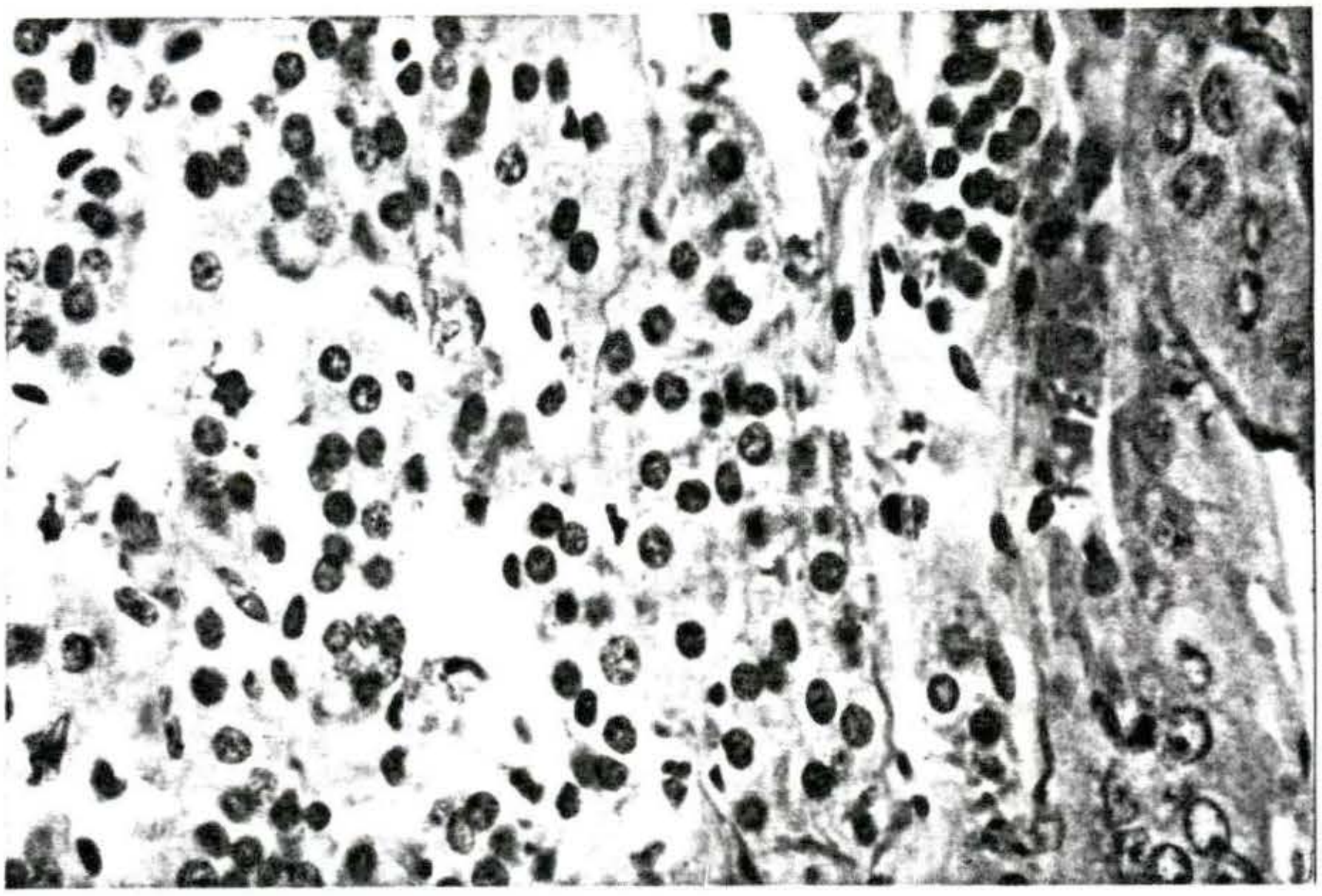

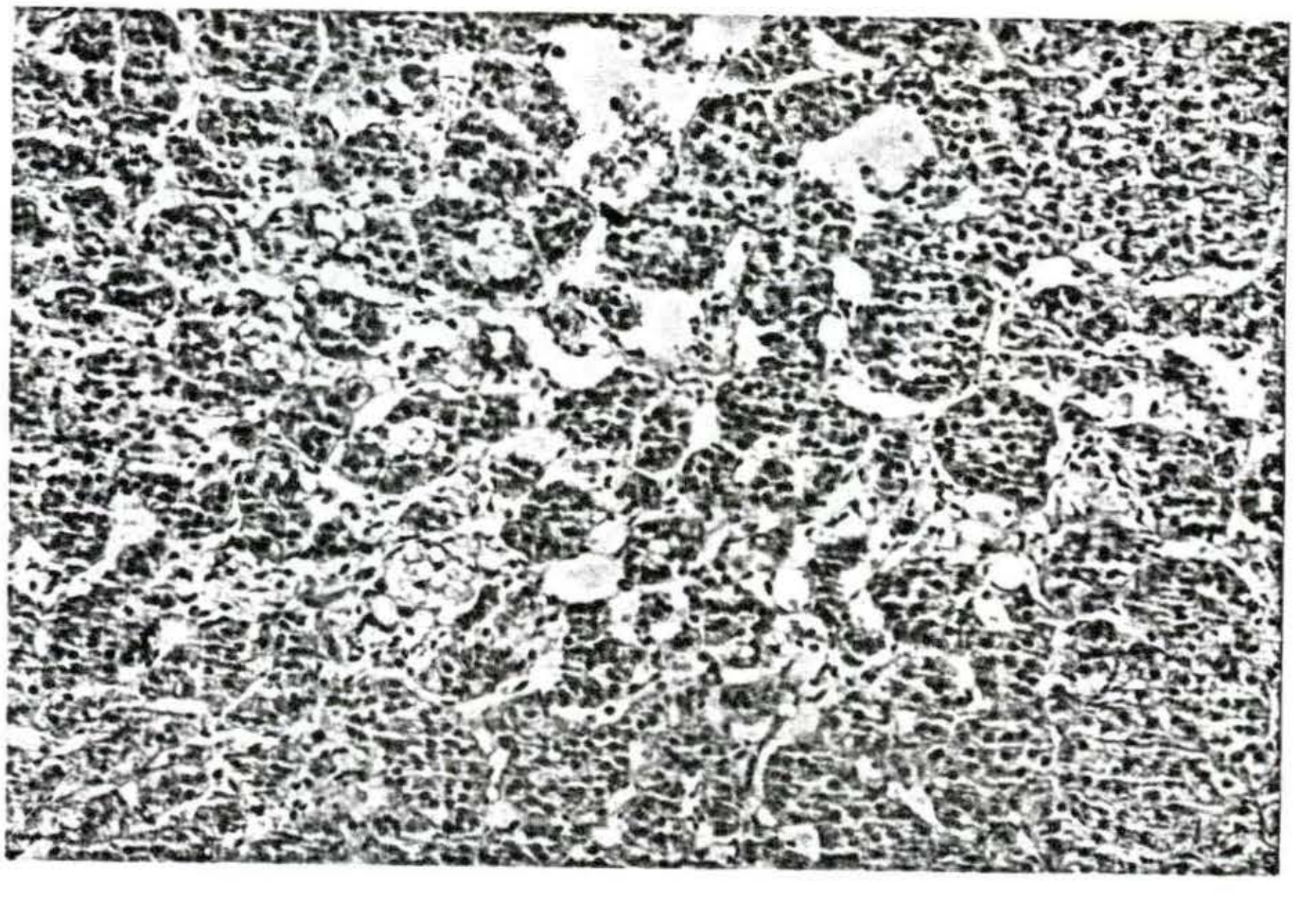

Fig. 34. Capsular blood vessel from adrenal of a 206-day old female canine (B61). Two vessels shown are of normal morphology. Note that the apex of the zona glomerulosa arcade is separated from the capsule by a capillary sinus. Observe the largely fibrous capsule gives rise to a cellular trabeculae in the glomerulosa. Heidenhain-Van Giesen-Weigert. Magnification X 1650.

Fig. 35. Capsular blood vessel from adrenal of a 3.4-year old male canine (B20). Artery is contained within a large trabeculae. The artery shows normal morphology. Stained with Heidenhain-Van Giesen-Weigert. Magnification X 1650.

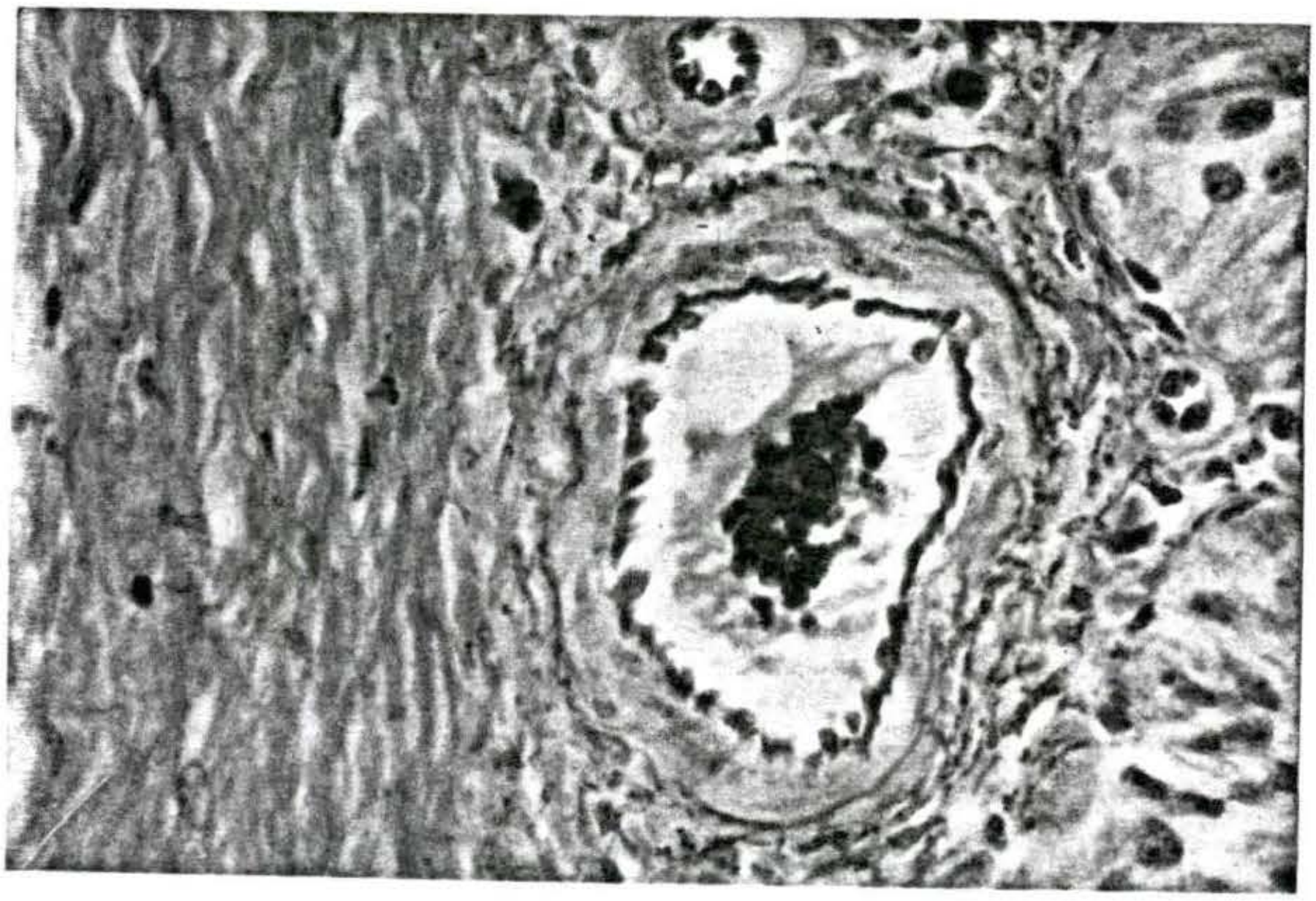

Fig. 36. Medullary blood vessel from adrenal of a 6.0-year old female canine (B18). The arterial vessel in center appears normal in morphology. The capillary sinuses which radiate from the area of this vessel seem to form a peripheral sinus around this artery. Note the large medullary sinus with only a thin endothelial cell lining. Stained with Heidenhain-Van Giesen-Weigert. Magnification X 1020.